

Anatomie van de anterieure bekkenregio

Dr. Jules Peeters
ASO fysische geneeskunde-revalidatie



Versie 1.0 20/04/2022



Indeling

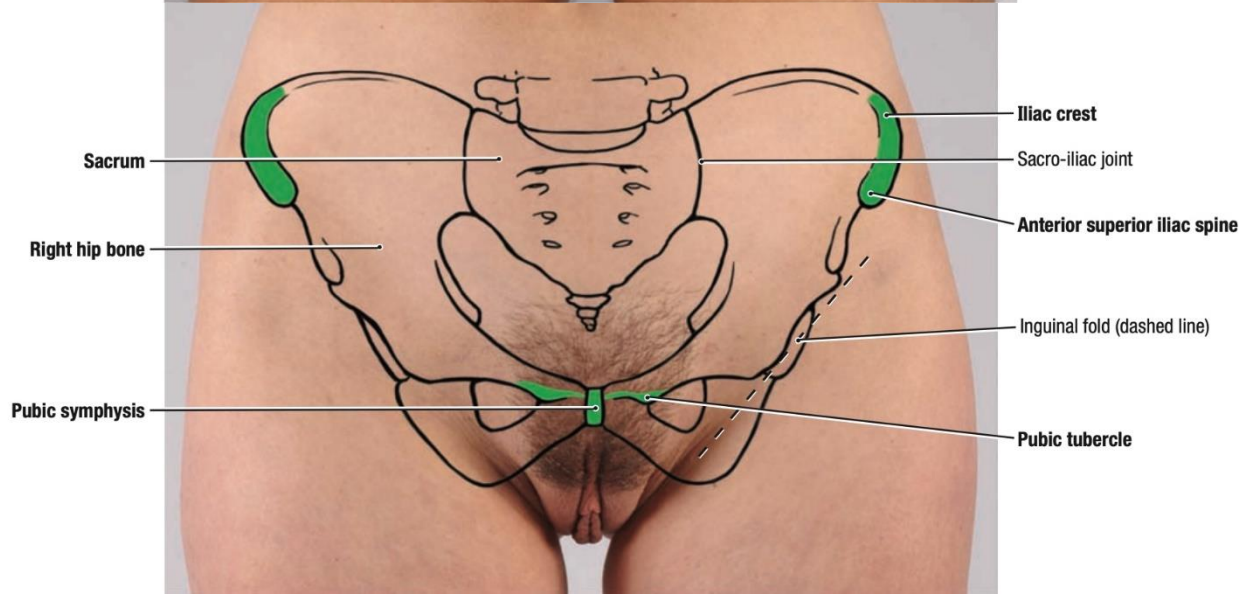
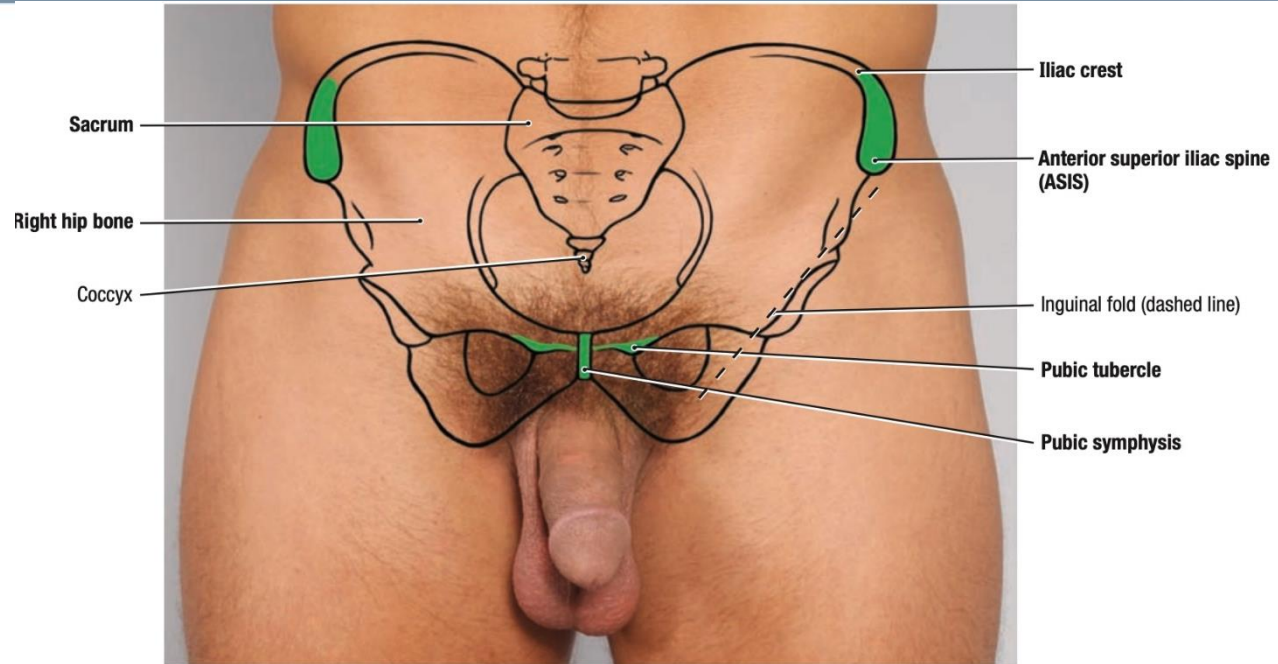
- Oppervlakte anatomie
- Osteo-articulair
- Ligamentair
- Musculair
- Vasculair
- Zenuwstructuren - distributiegebied



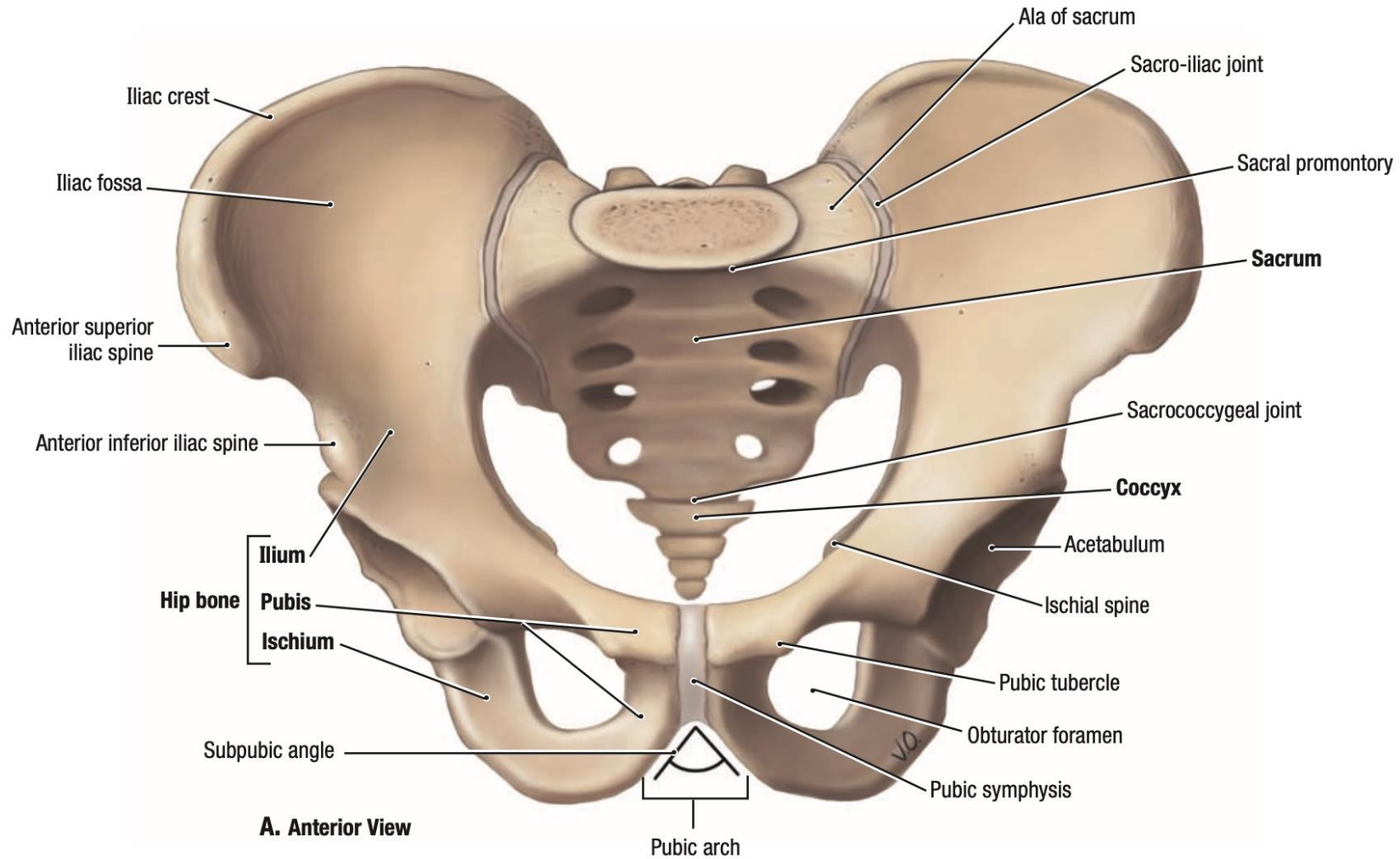
Versie 1.0 20/04/2022



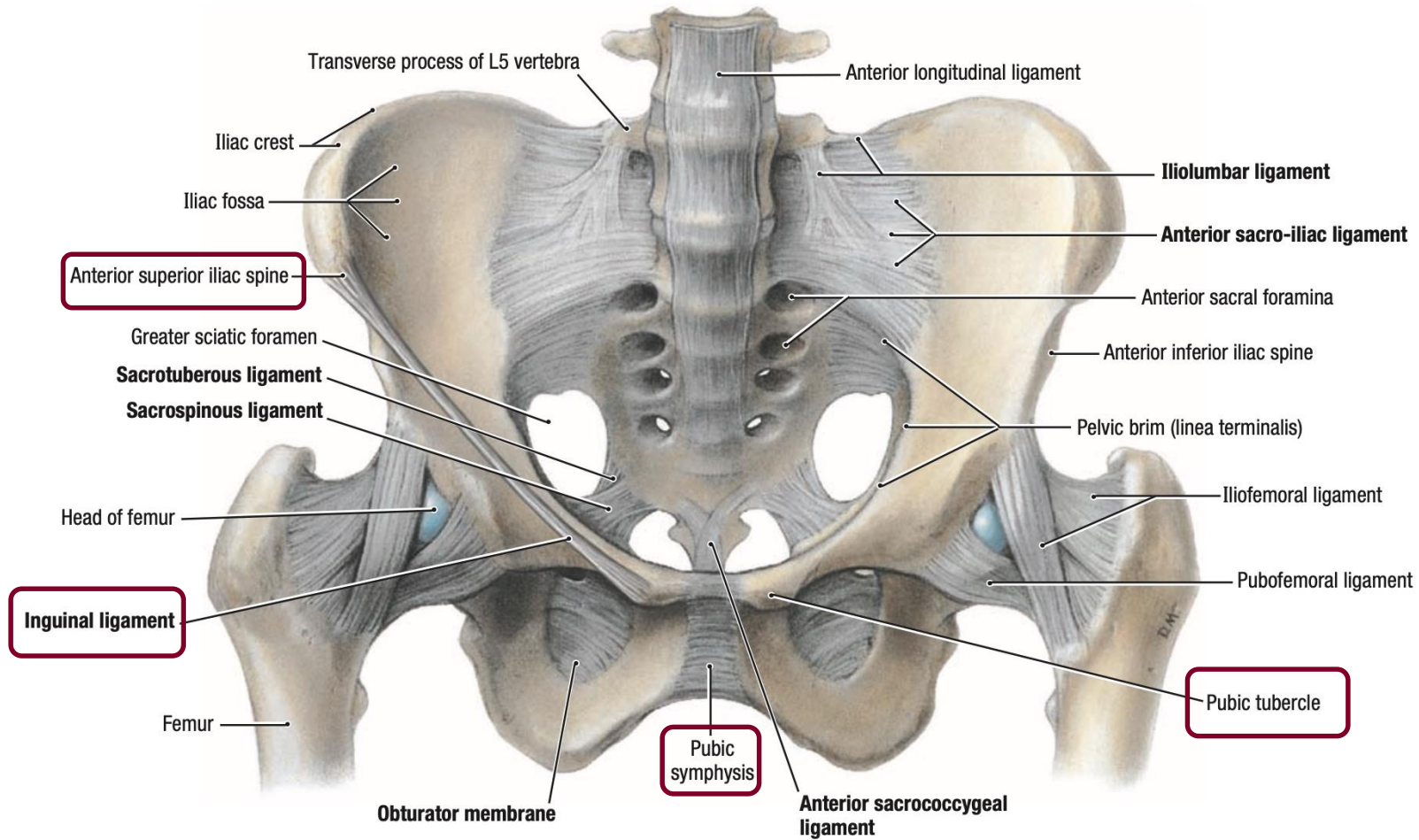
Oppervlakte anatomie



Osteo-articulaire

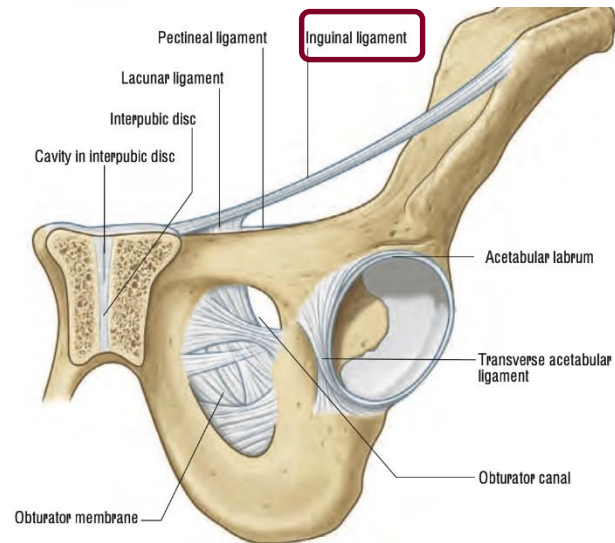
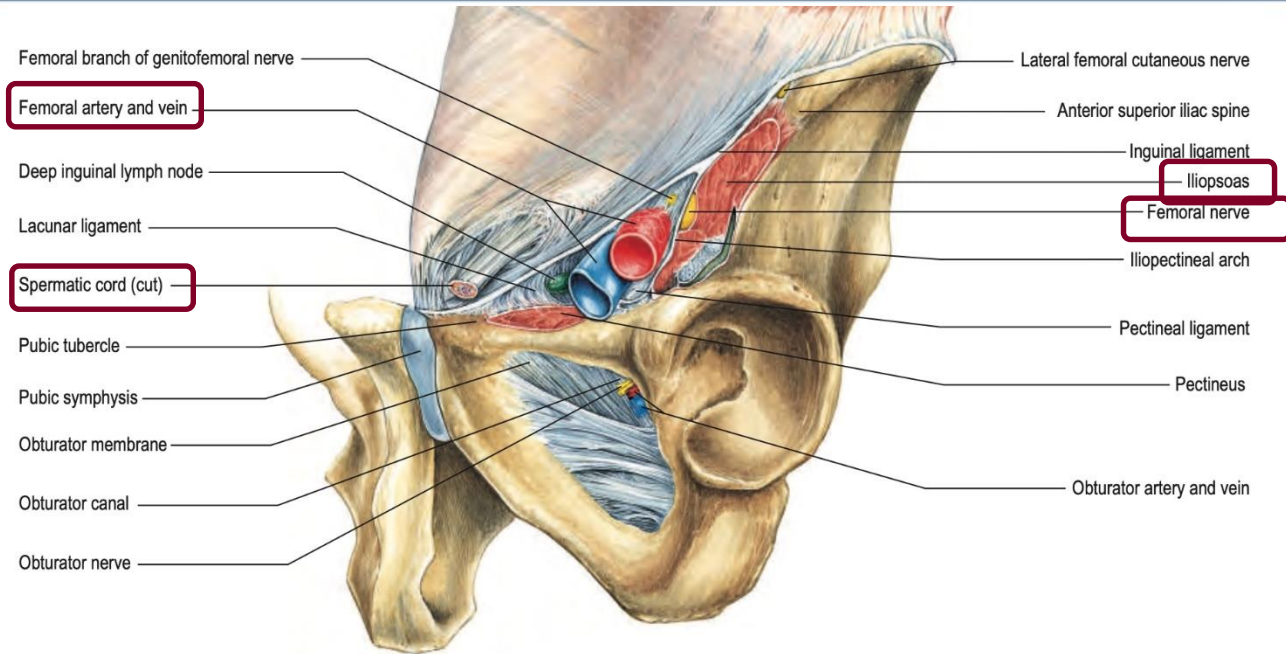


Ligamentair

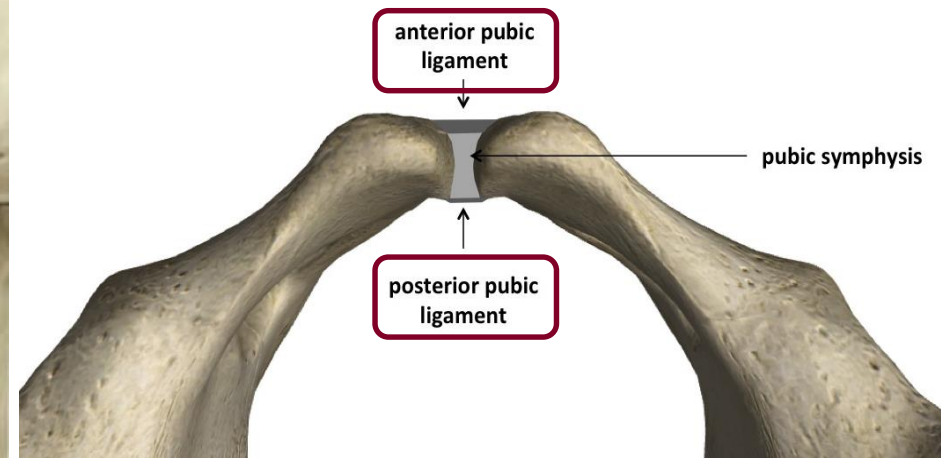
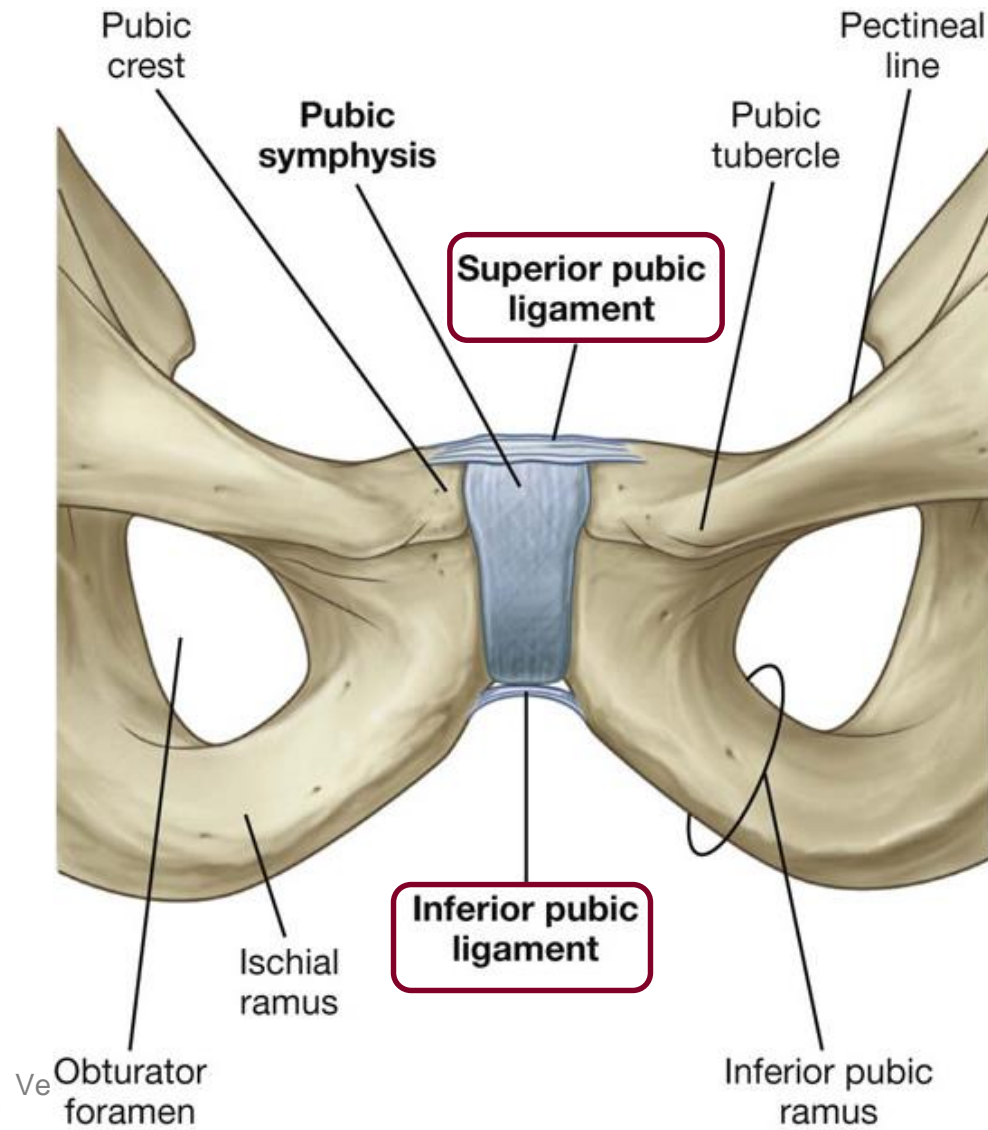


A. Anterior View

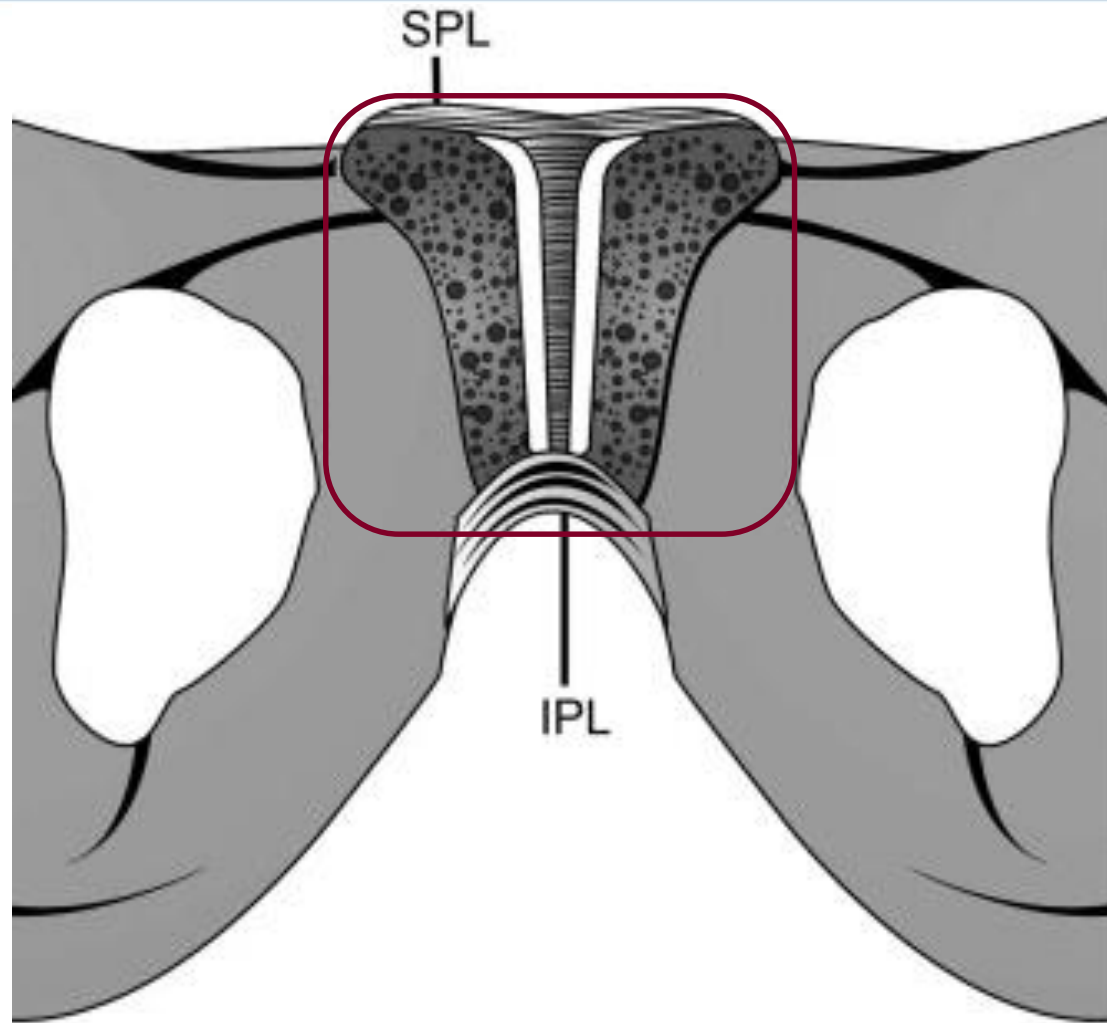
Ligamentair



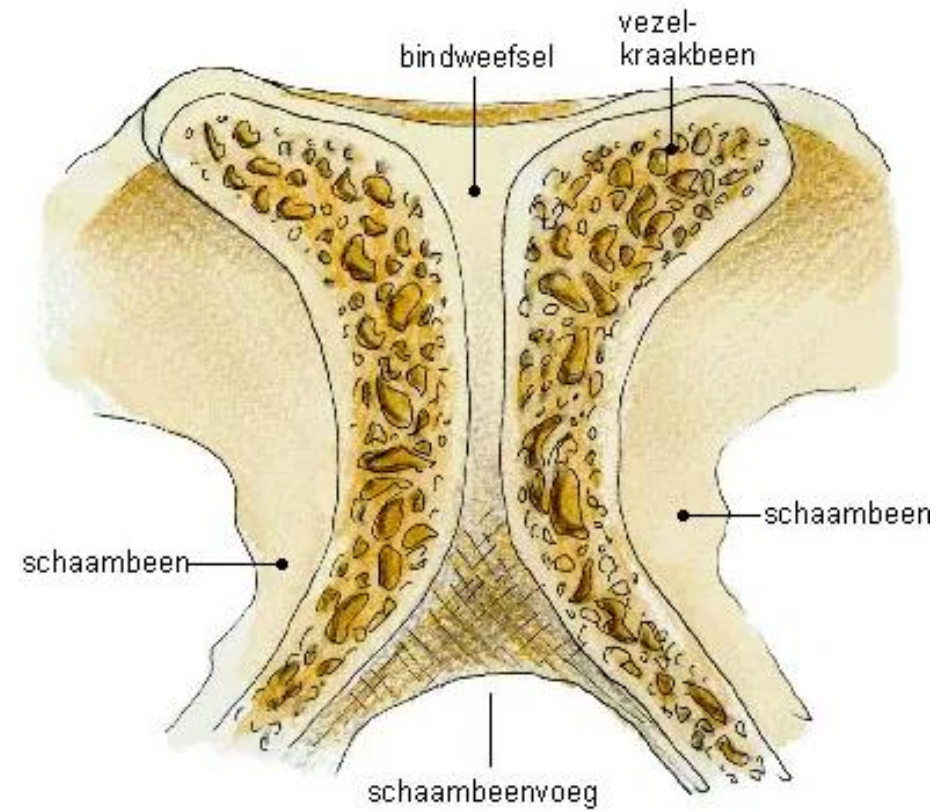
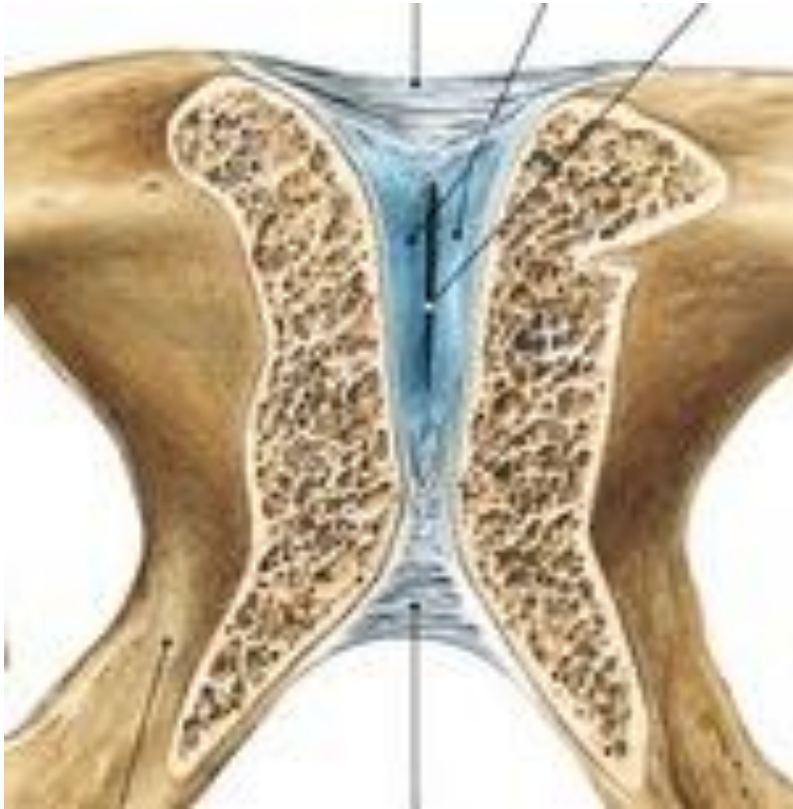Ligamentair



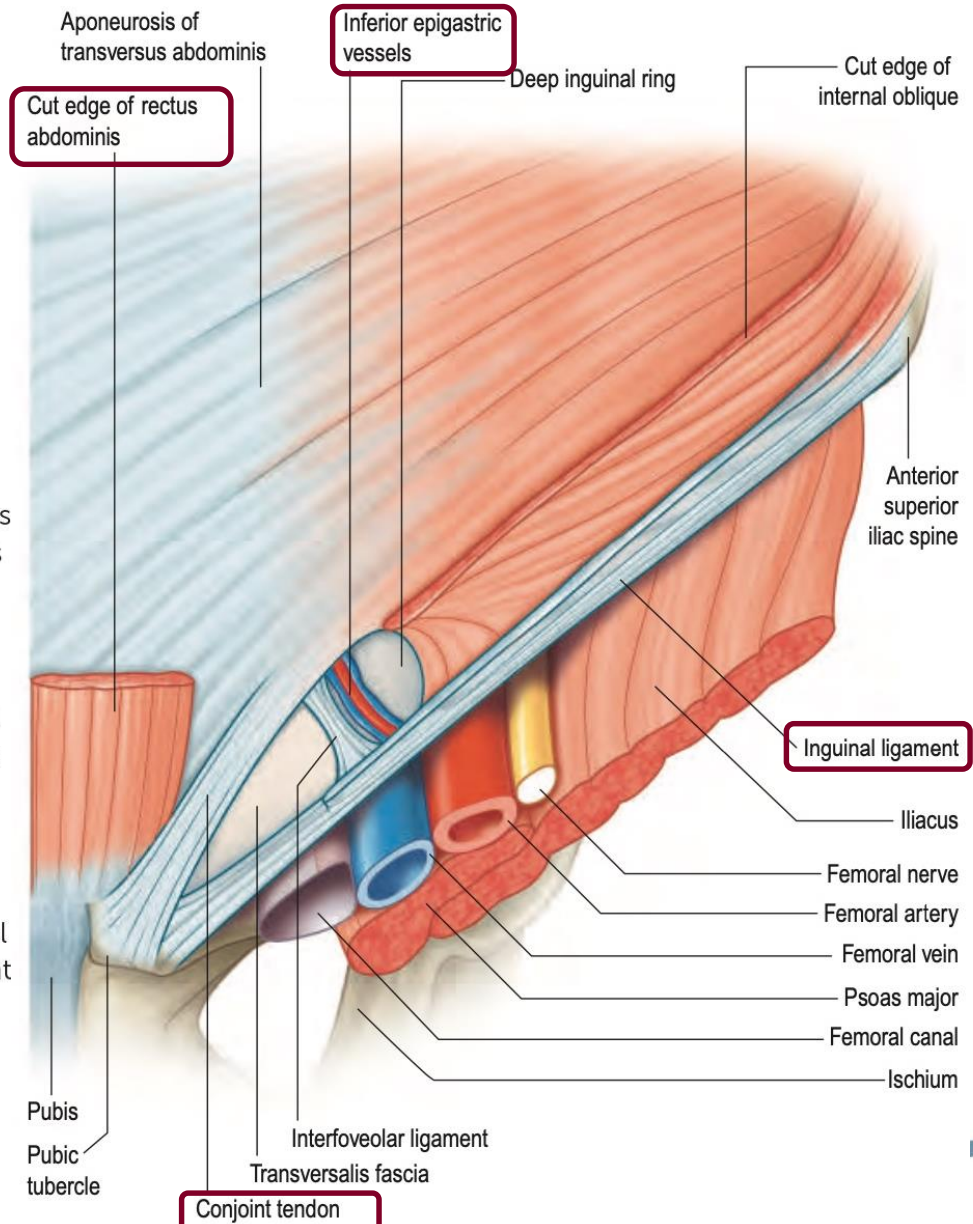
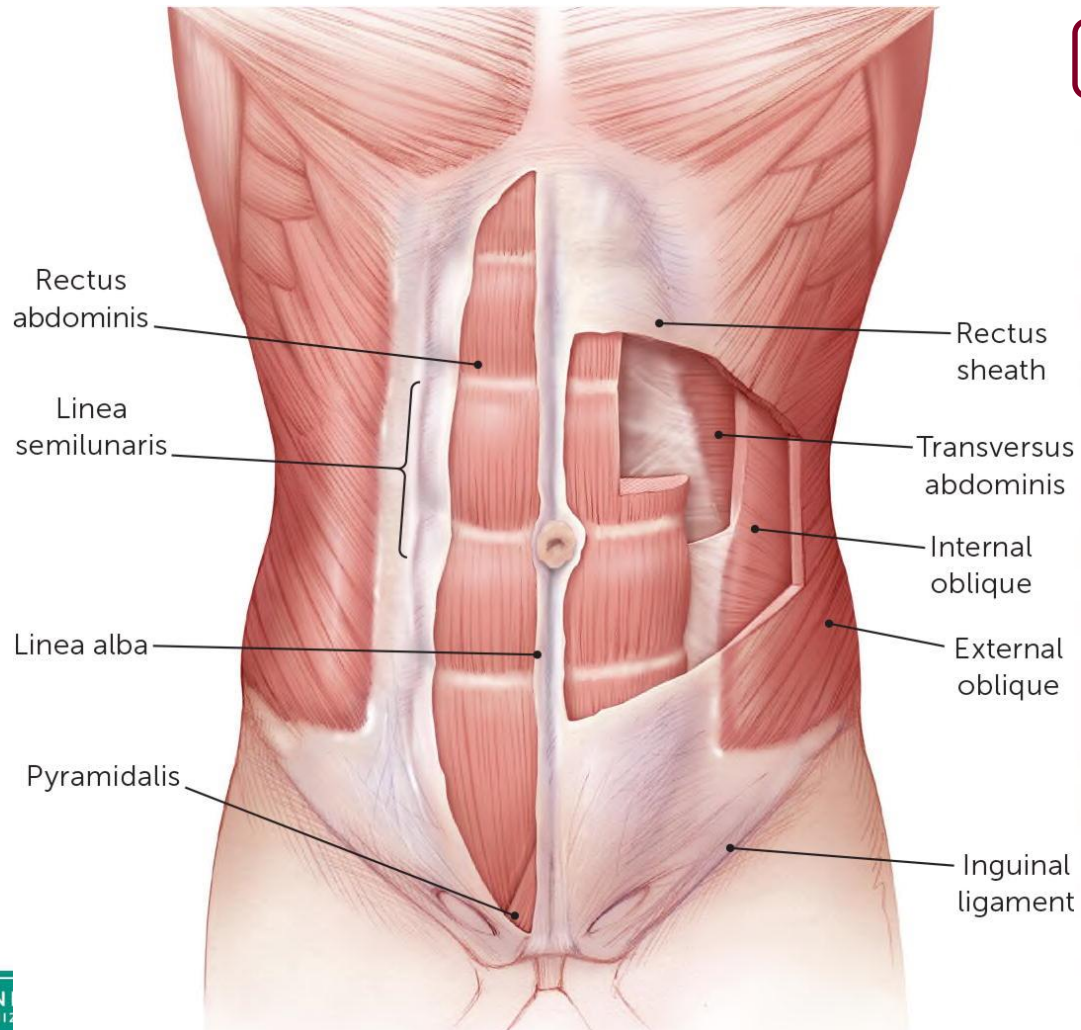
Discus interpubicus



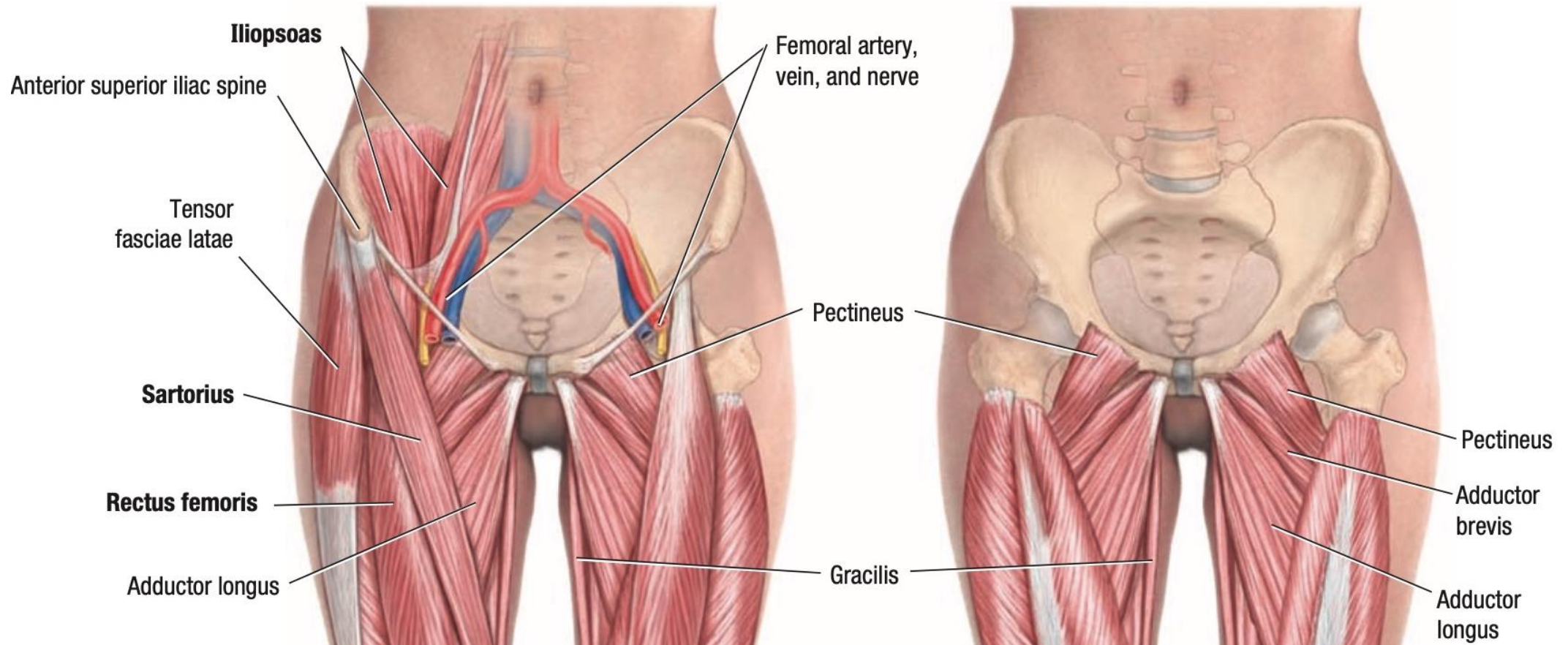
Discus interpubicus



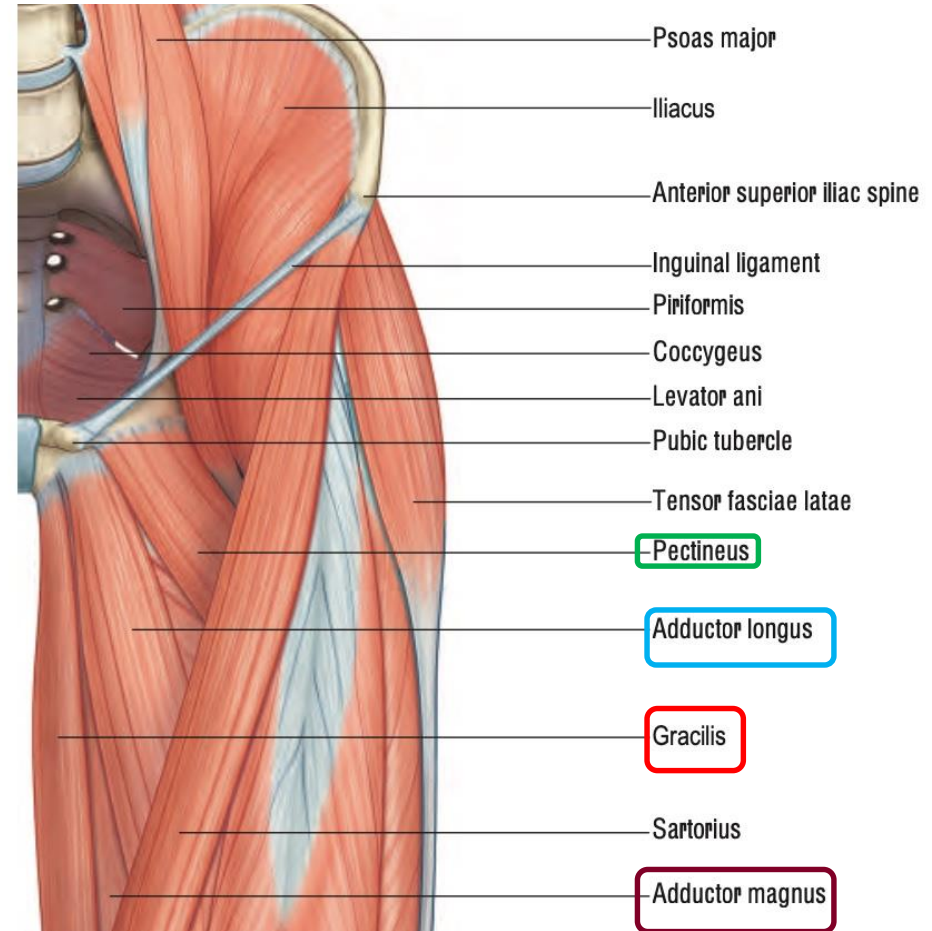
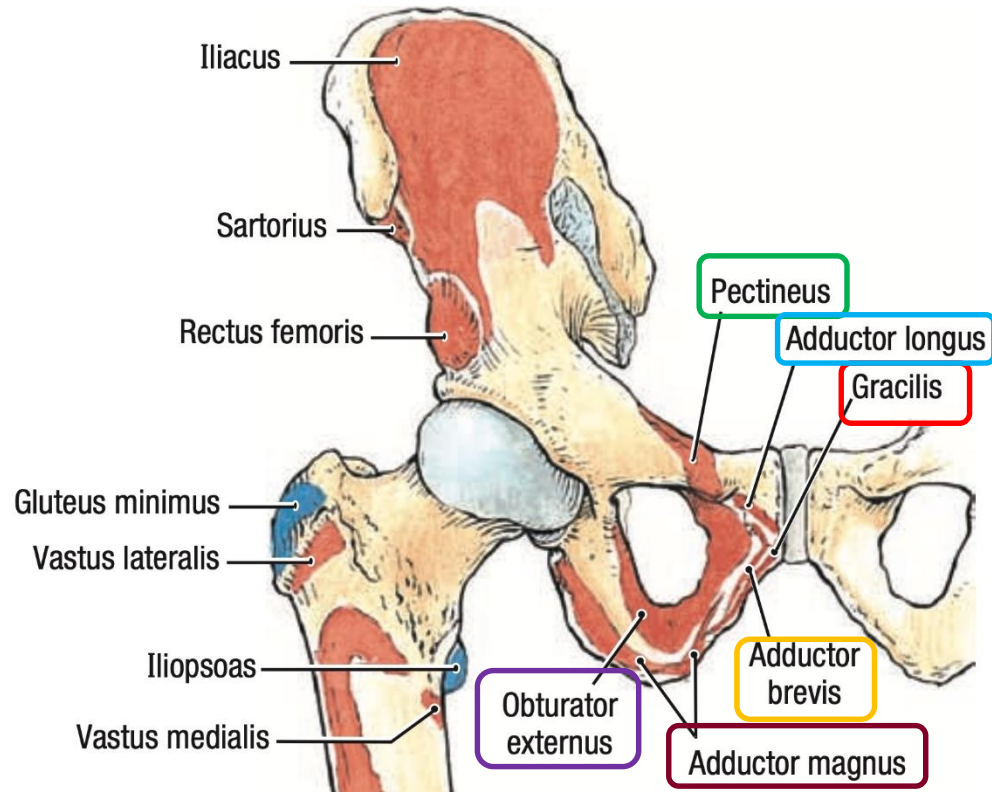
Musculair: buikwand



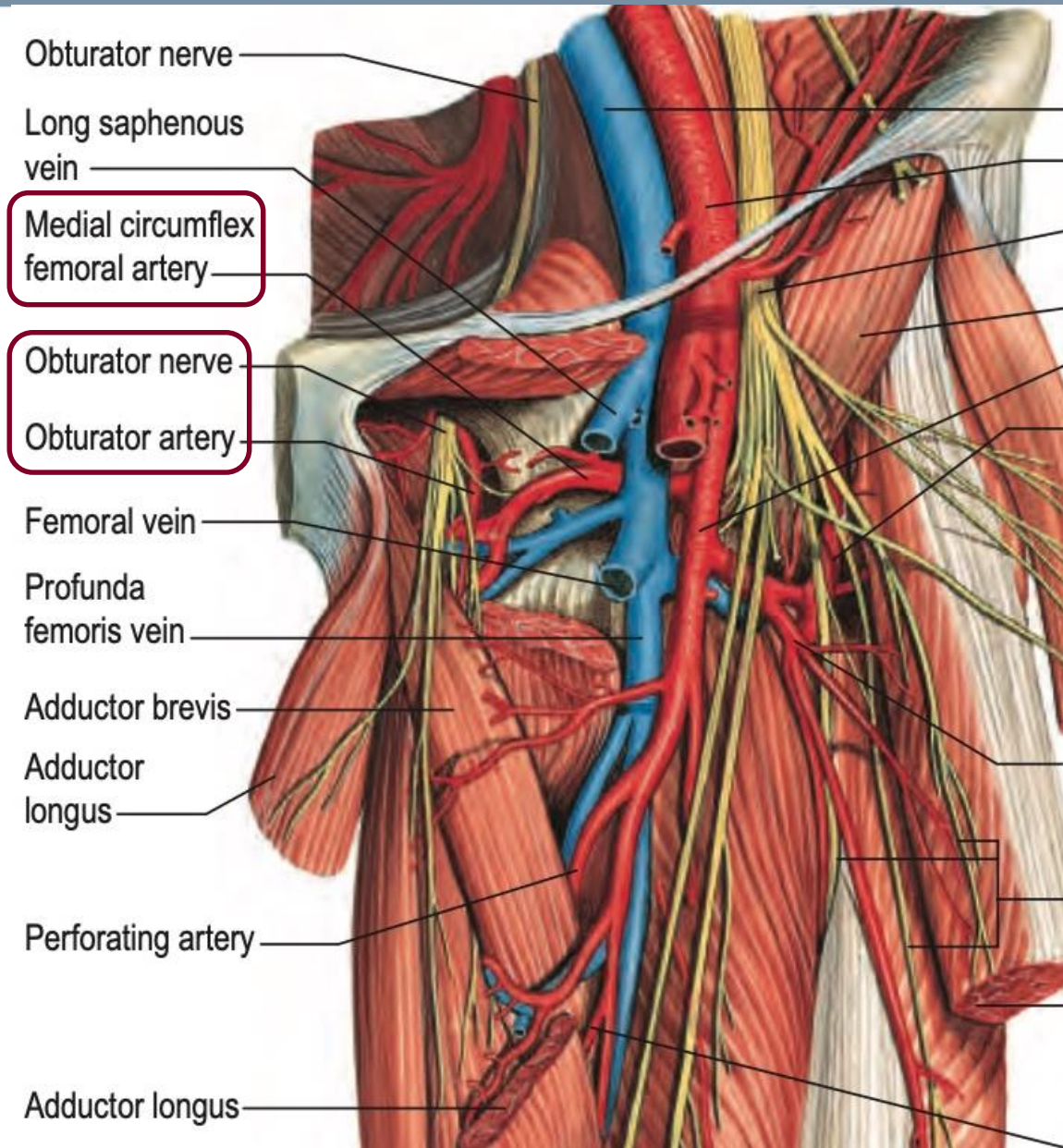
Musculair: liesregio



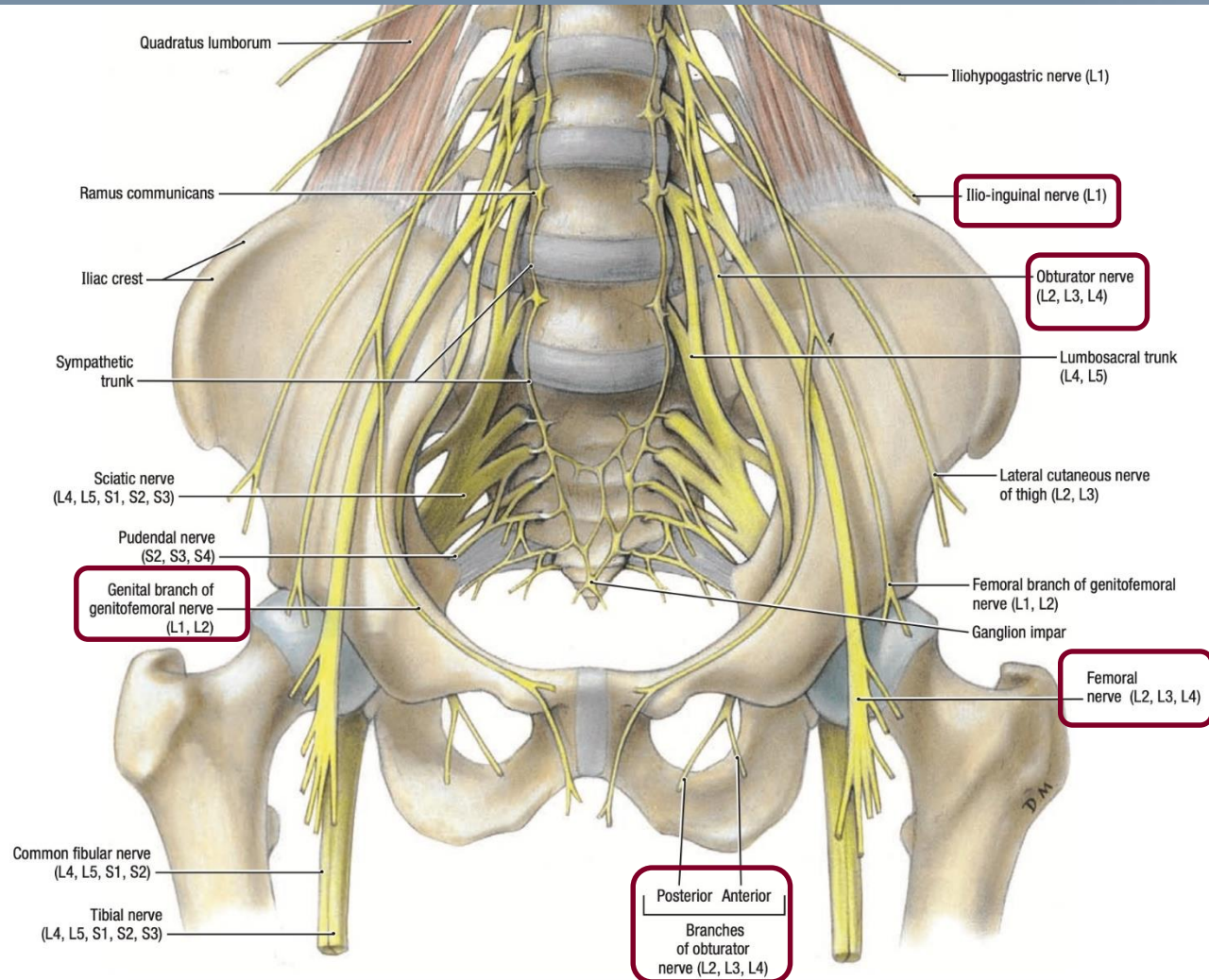
Musculair: liesregio



Vasculair

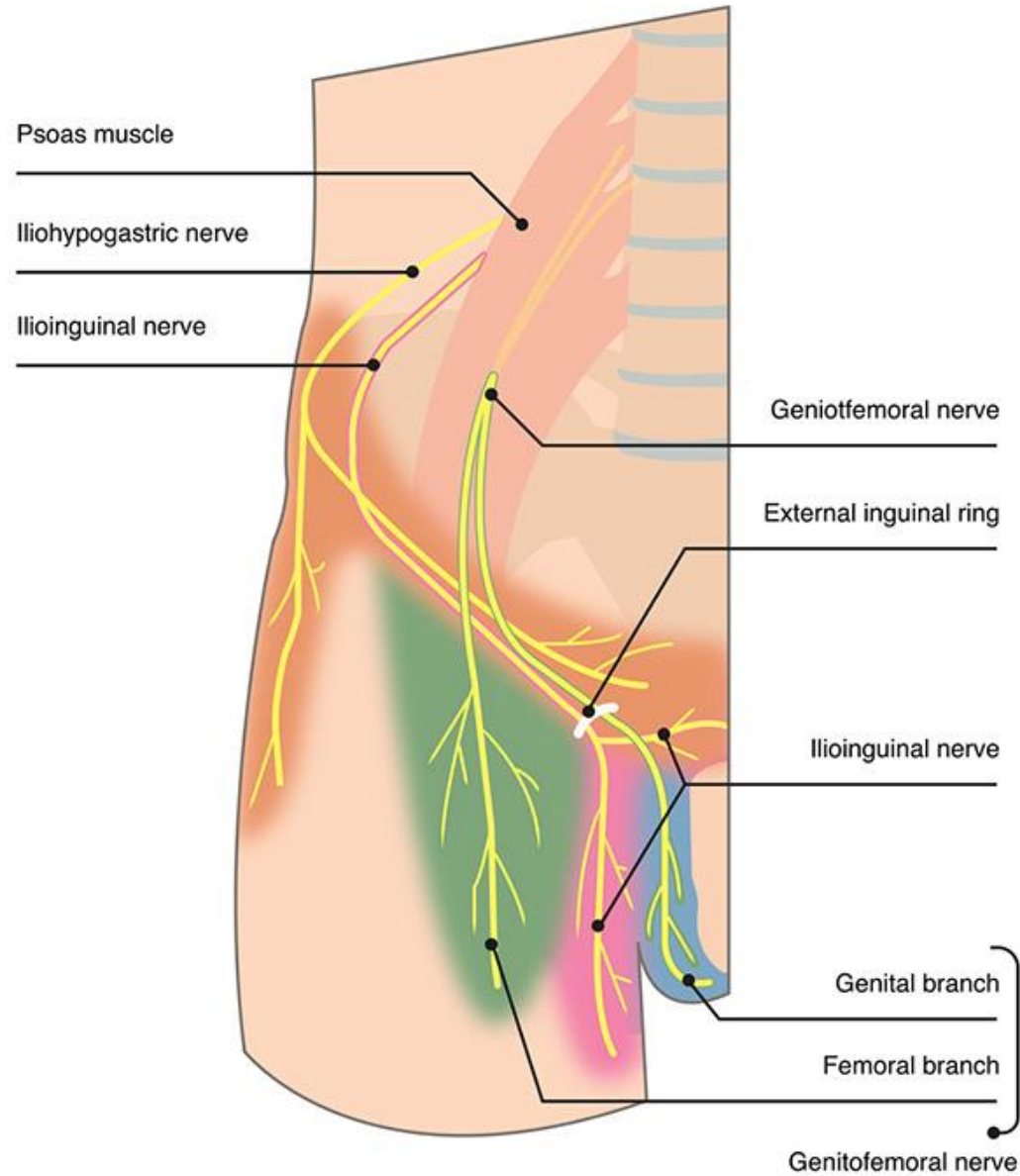


Zenuwstucturen



A. Anterior View

Distributiegebied



> [Ann Anat.](#) 2022 May 31;244:151959. doi: 10.1016/j.aanat.2022.151959. Online ahead of print.

New insights into the musculotendinous and ligamentous attachments at the pubic symphysis: A systematic review

Thomas Mathieu ¹, Francis Van Glabbeek ², Luc Van Nassauw ³, Katrien Van Den Plas ³,
Lenie Denteneer ⁴, Gaëtane Stassijns ⁴



Versie 1.0 20/04/2022



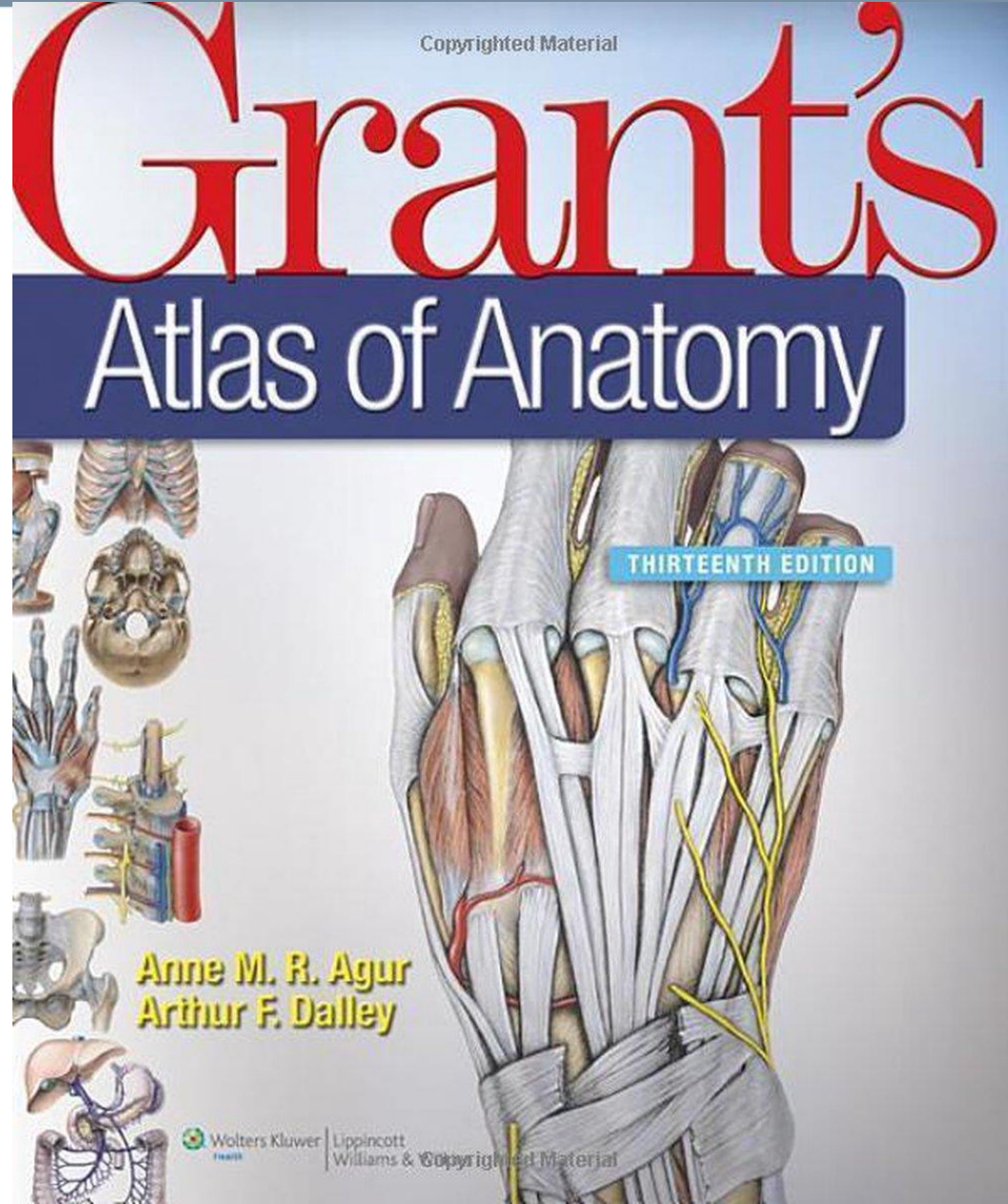


Bedankt voor de aandacht!



Versie 1.0 20/04/2022





Versie 1.0 20/04/2022

