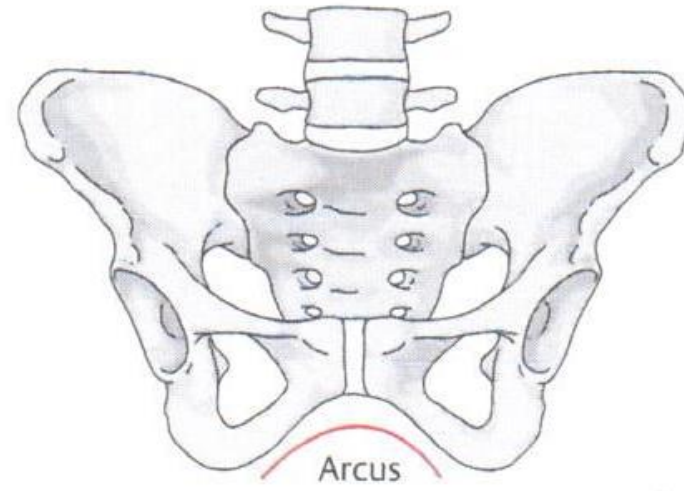


PUBALGIE (...> 3-6m)

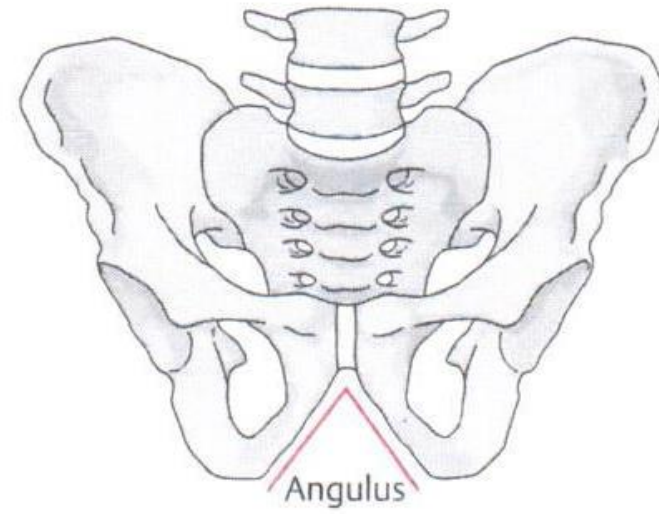
**Zin en onzin van
Manuele therapie**

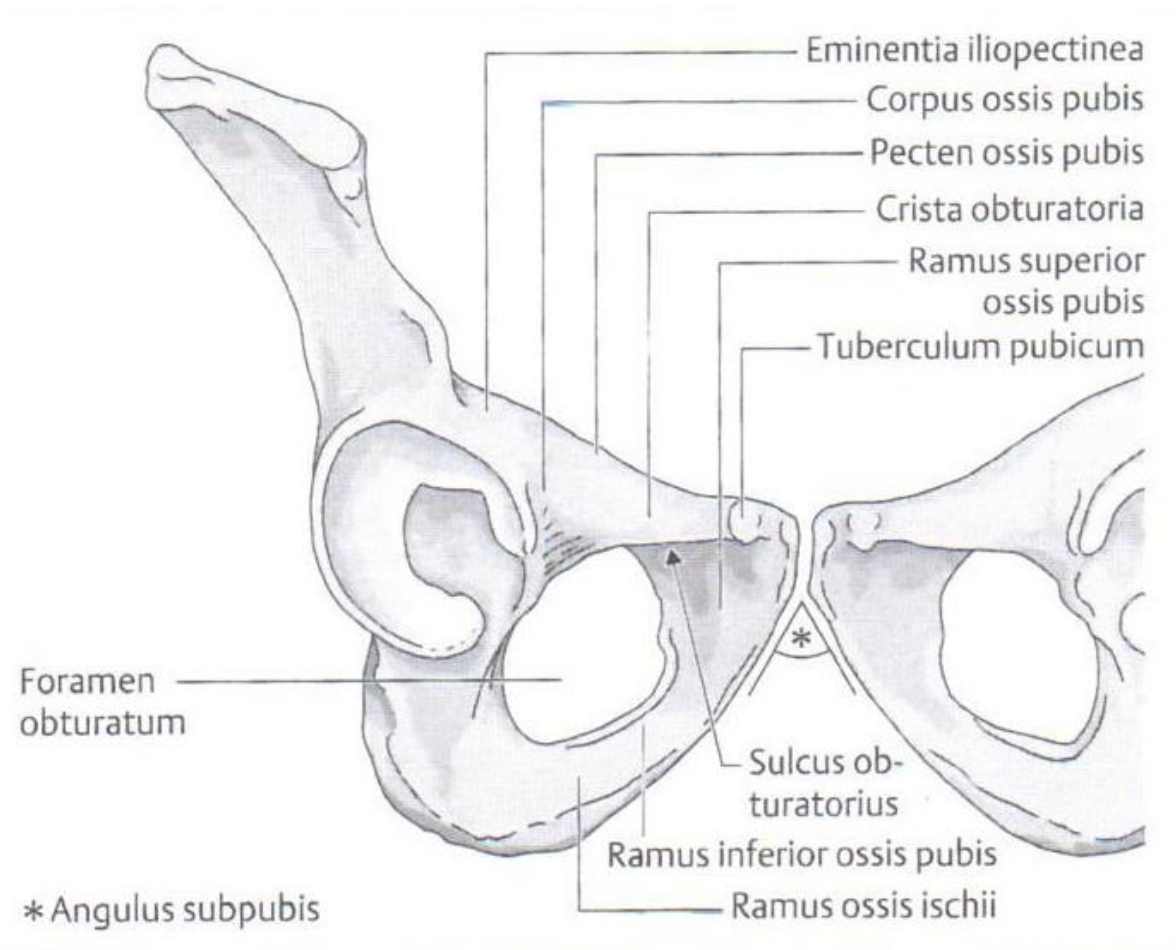


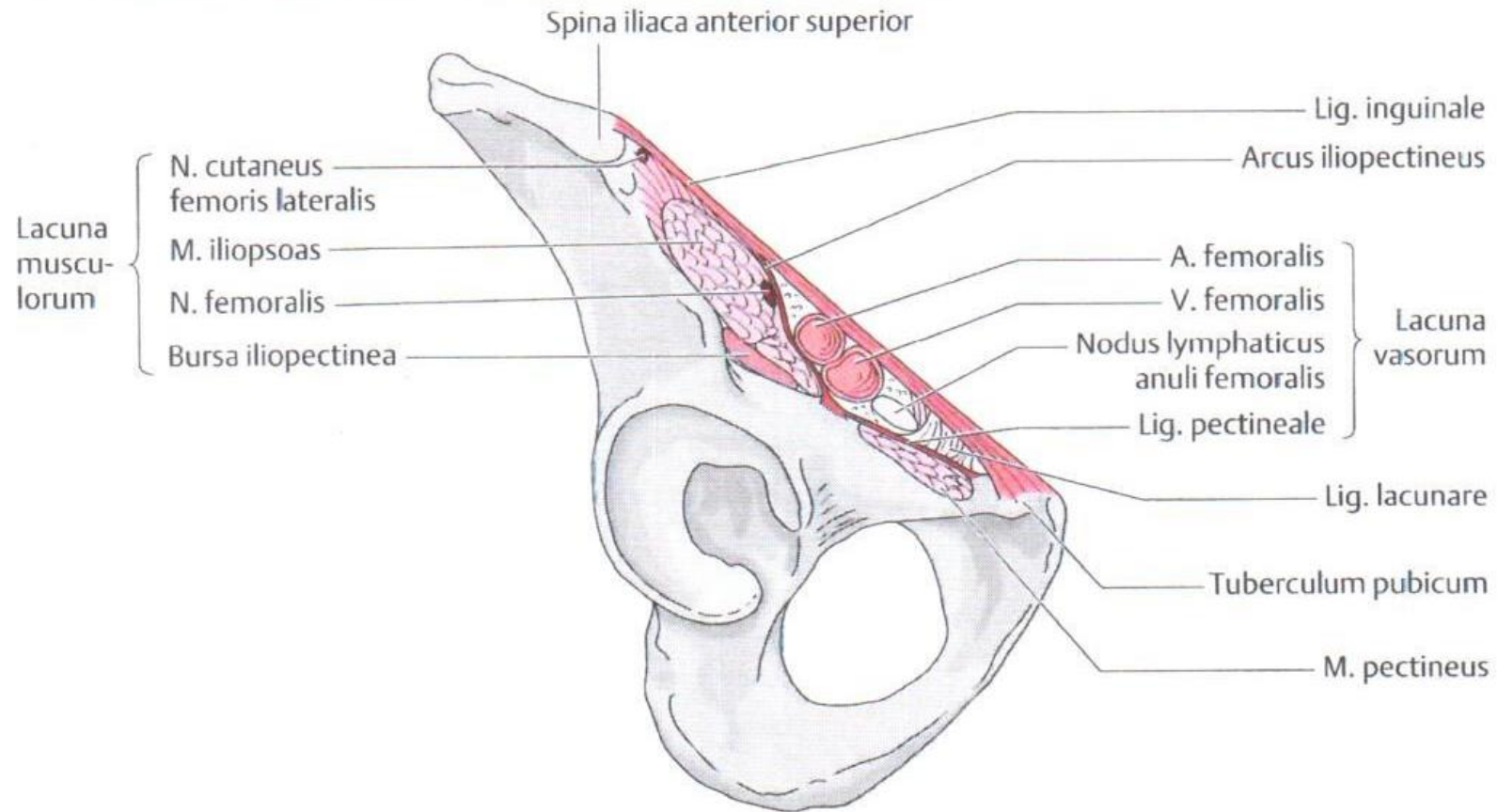
a

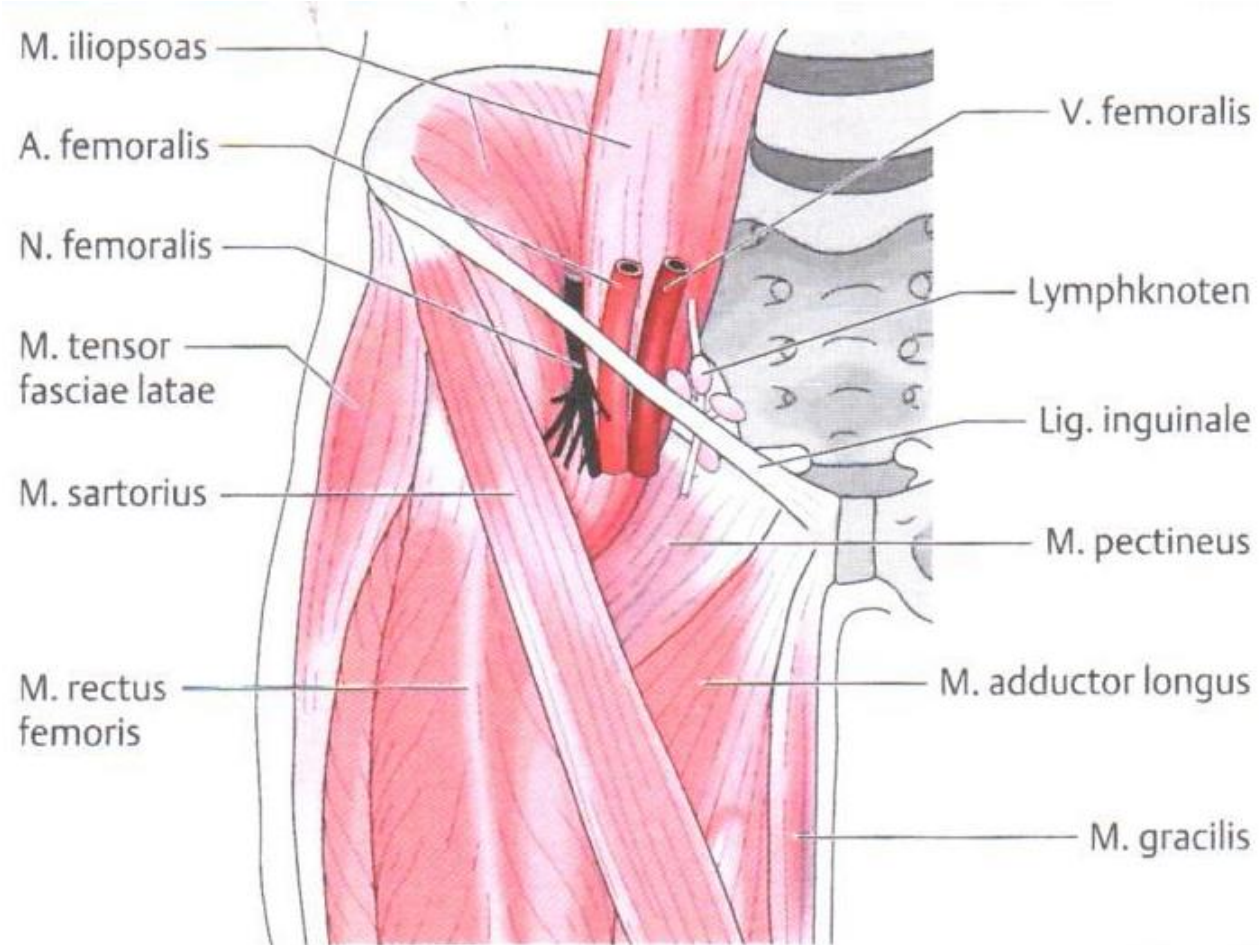


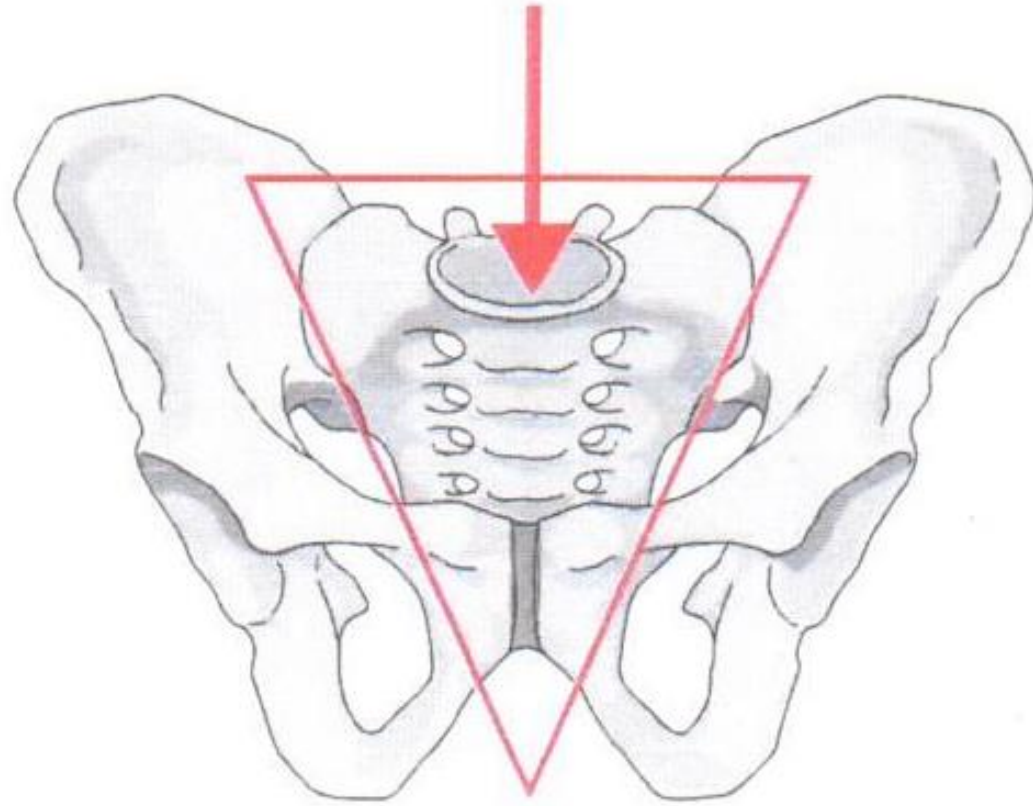
b



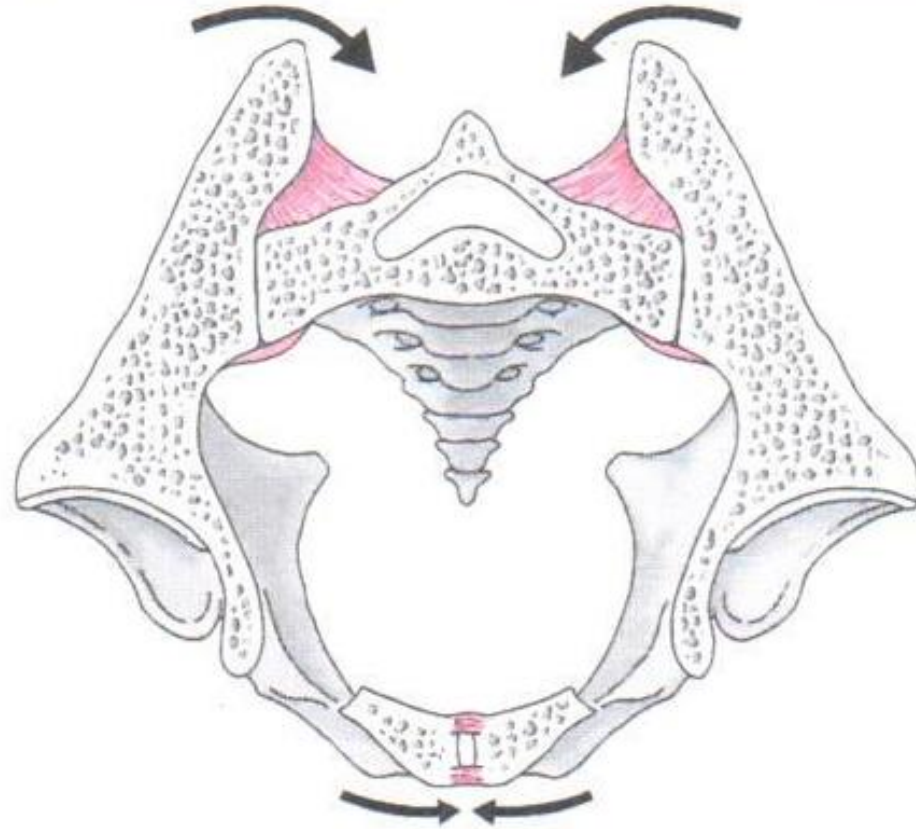


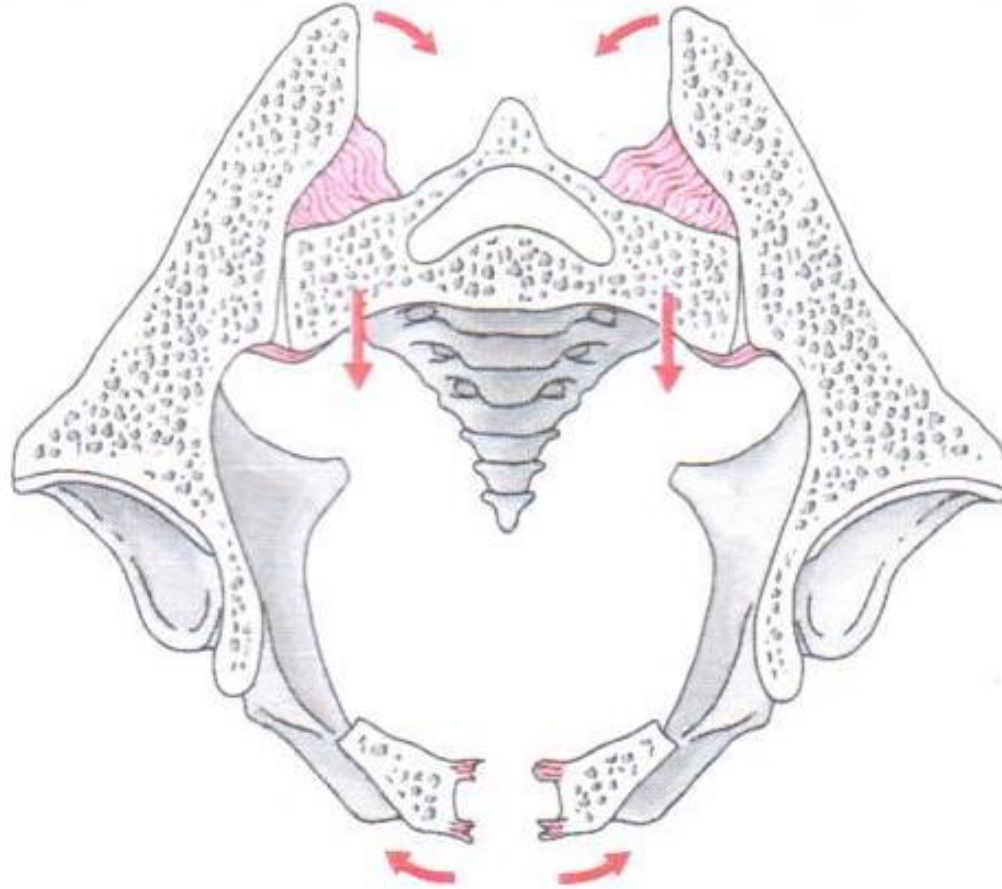


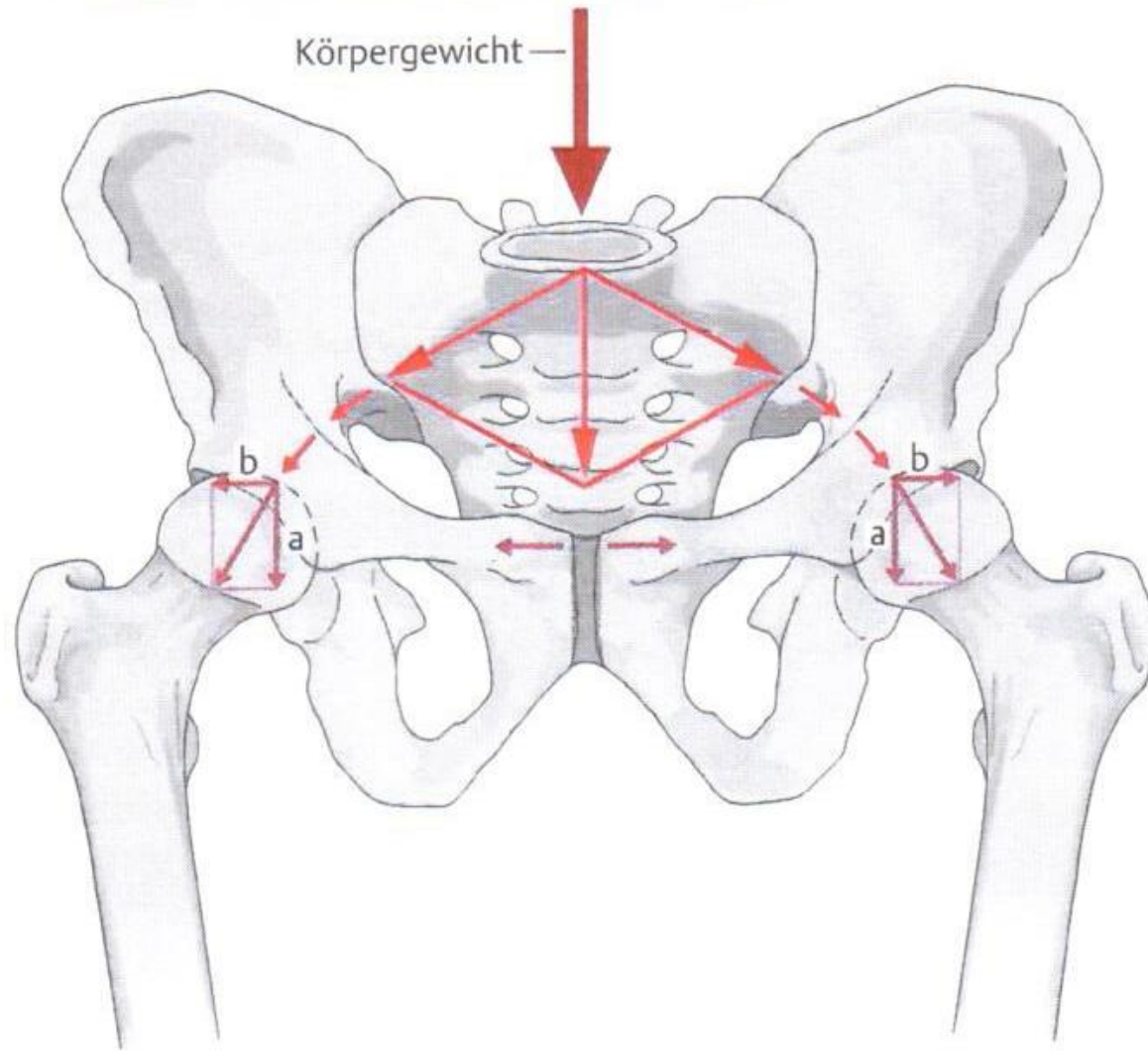


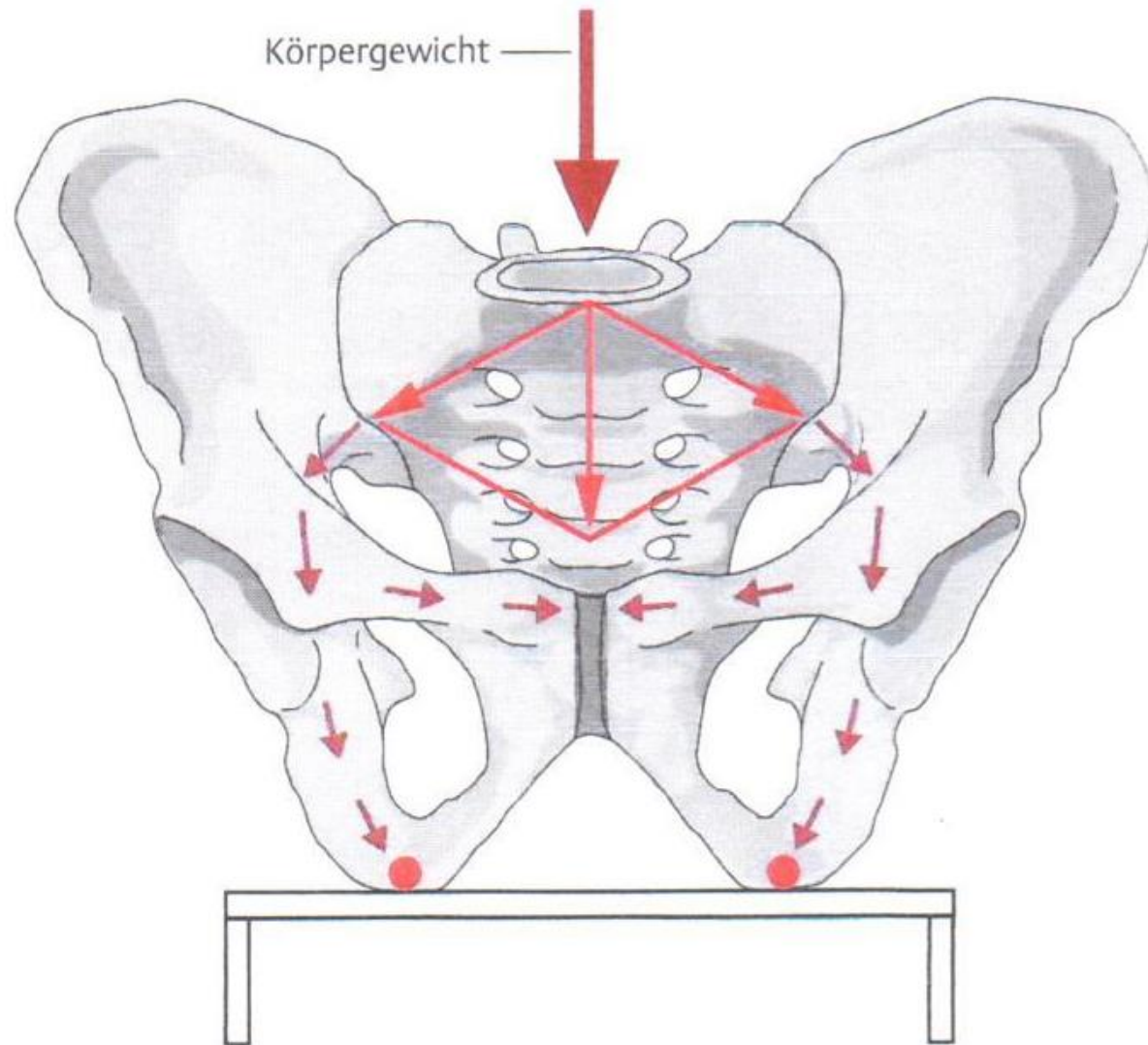


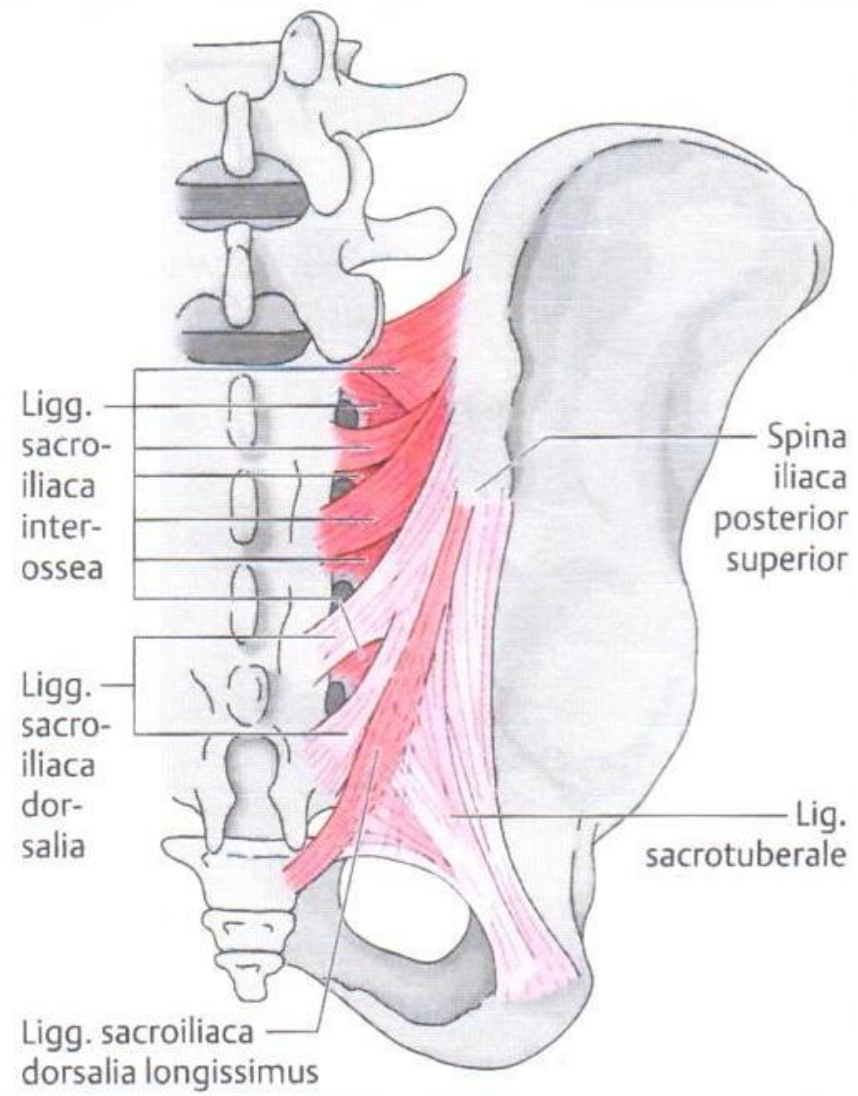


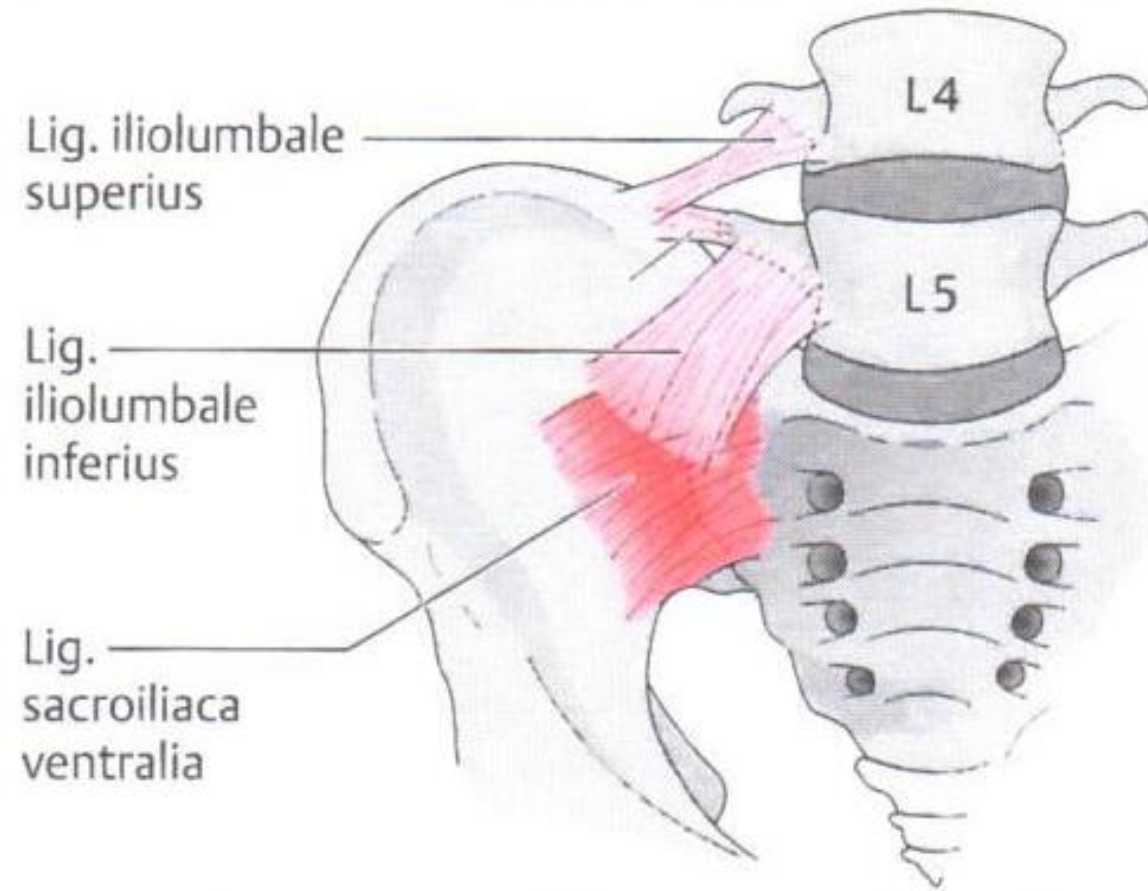


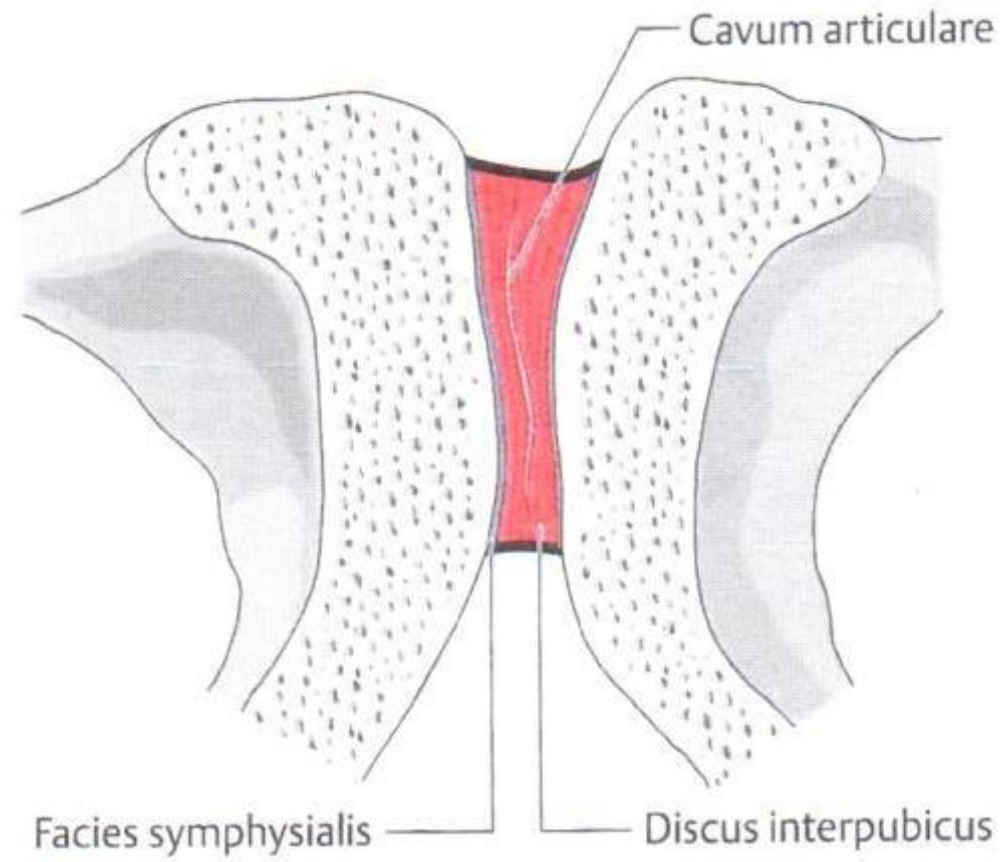


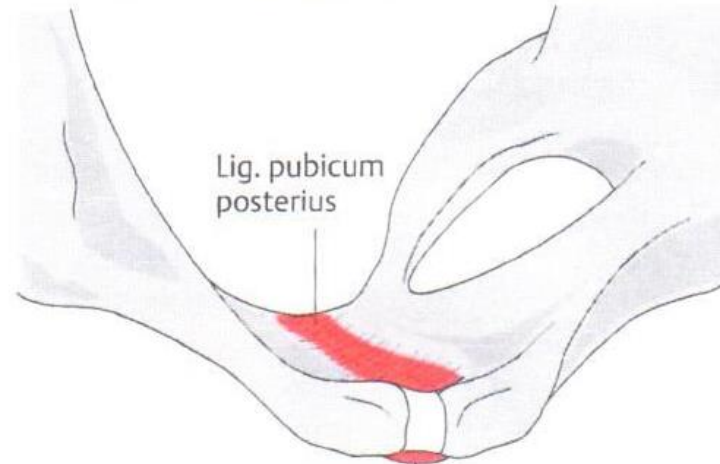










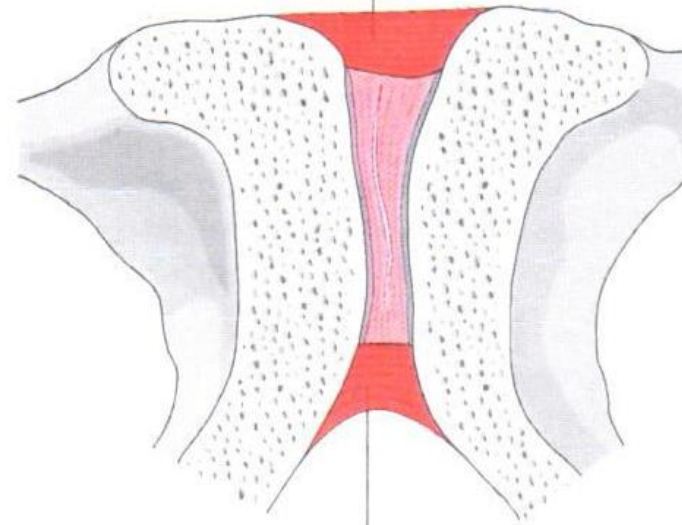


a

Lig. pubicum
posterius

Lig. pubicum
anterior

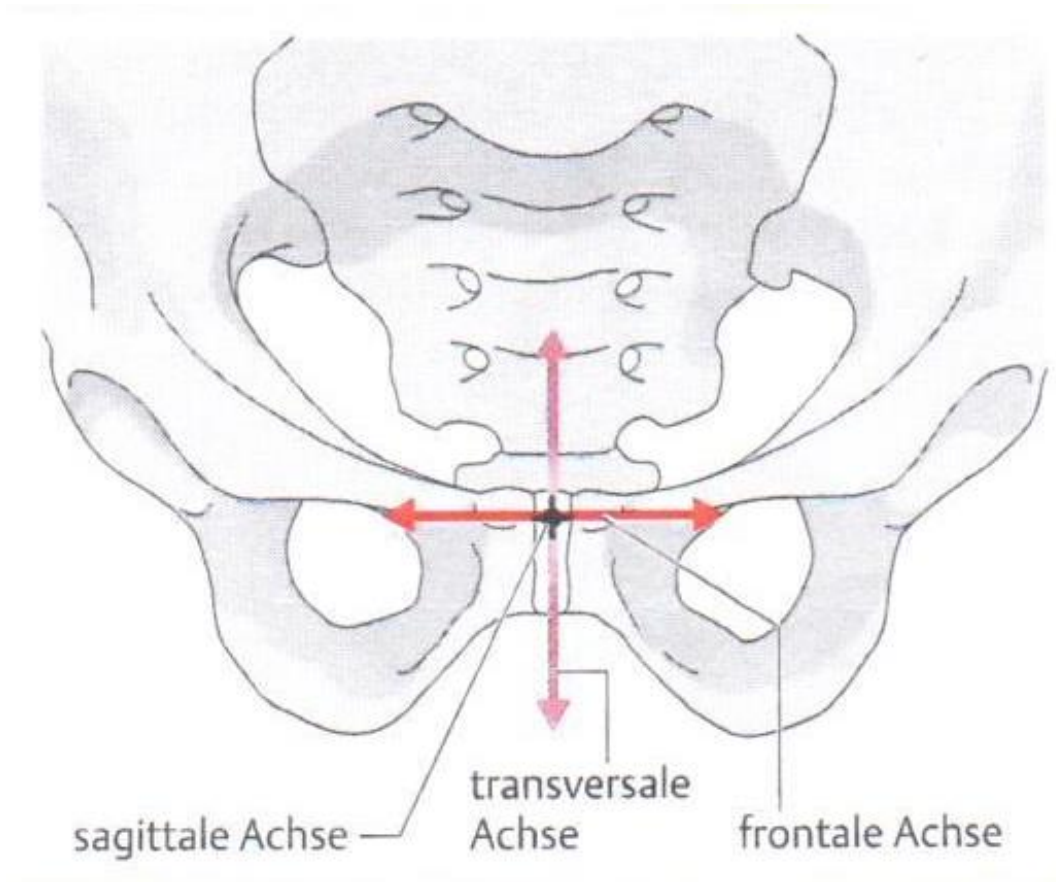
Lig. pubicum
superius

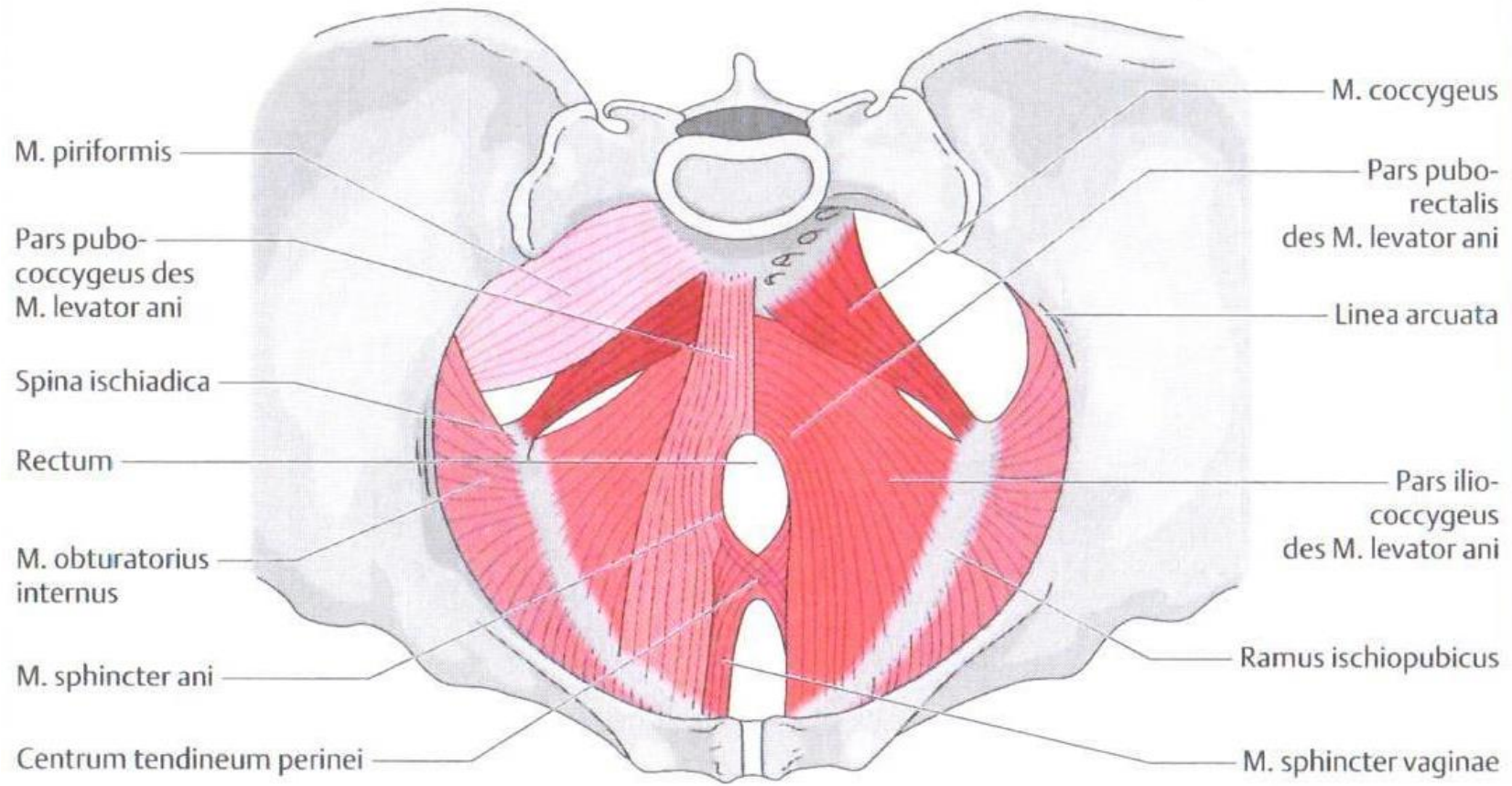


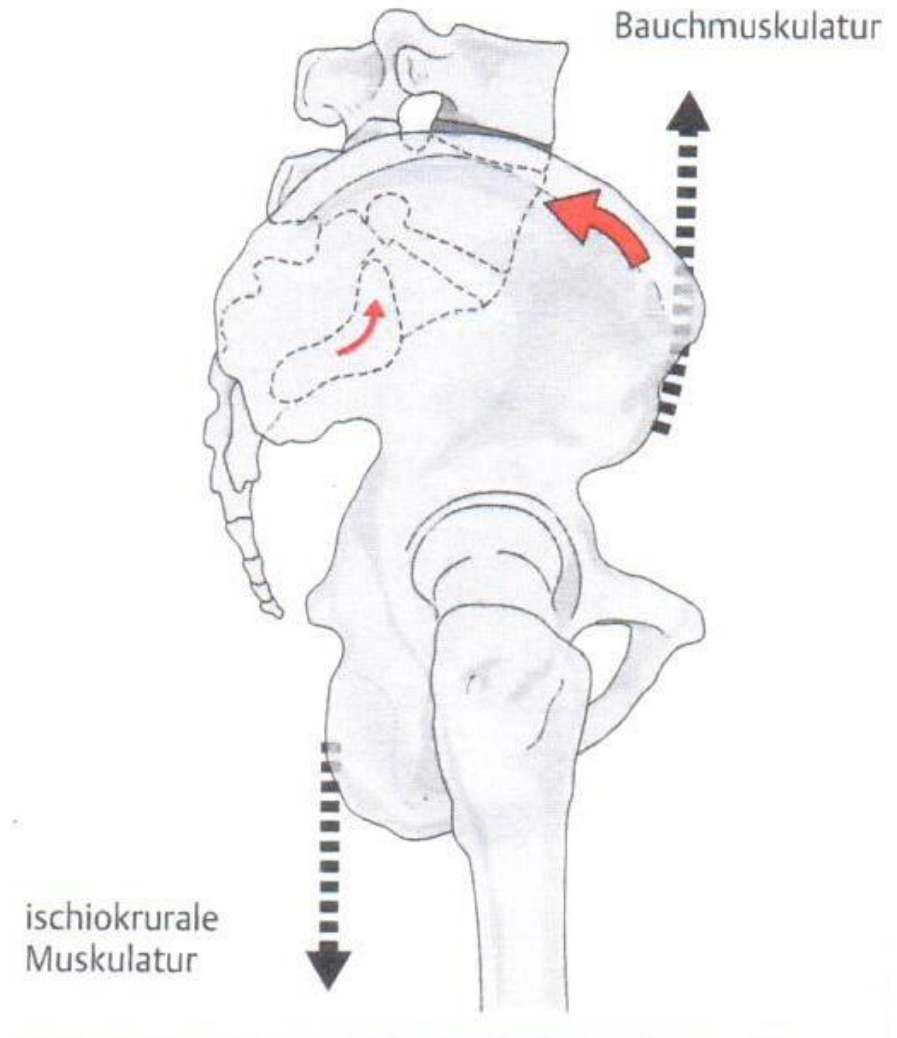
b

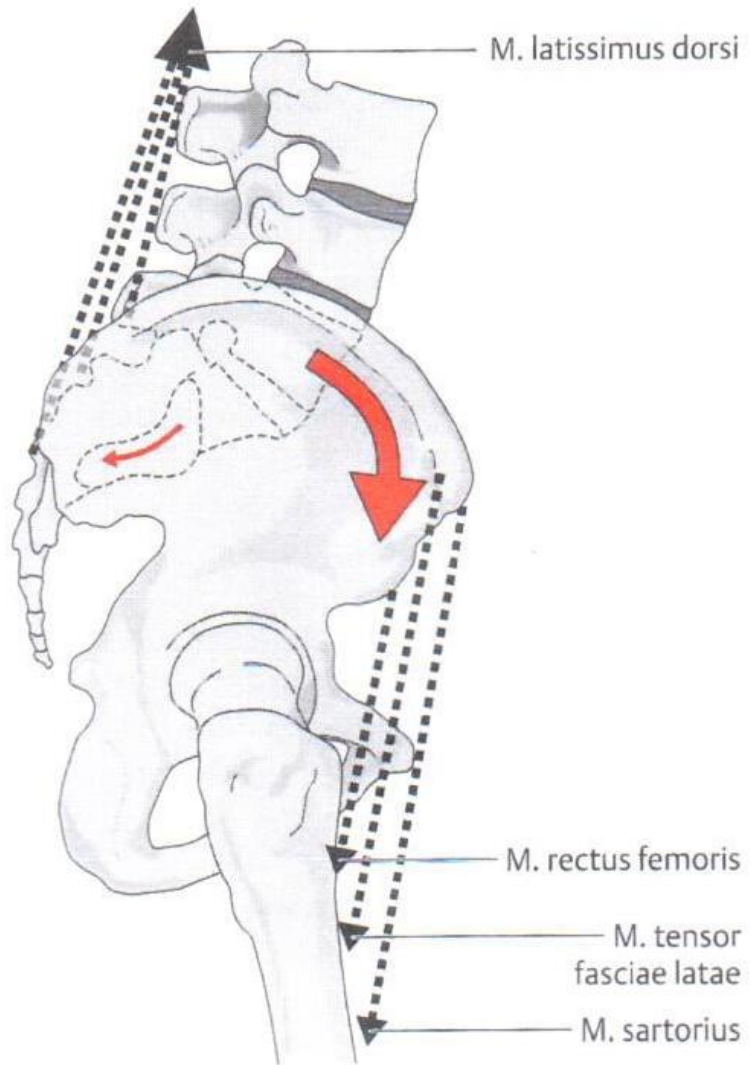
Lig. arcuatum
pubis











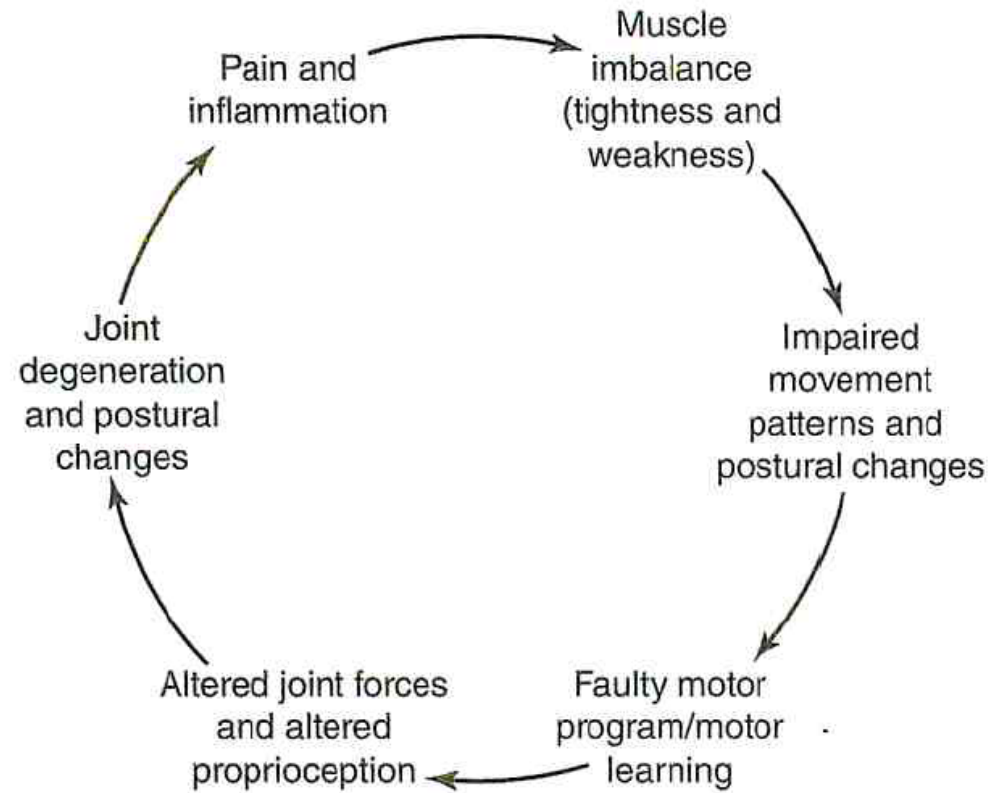


Figure 4.1 The chronic musculoskeletal pain cycle presented from a neurological perspective.



- ARTROKINEMATICA (GEWRICHTSMECHANICA)

primeert op

- SPIERMECHANICA

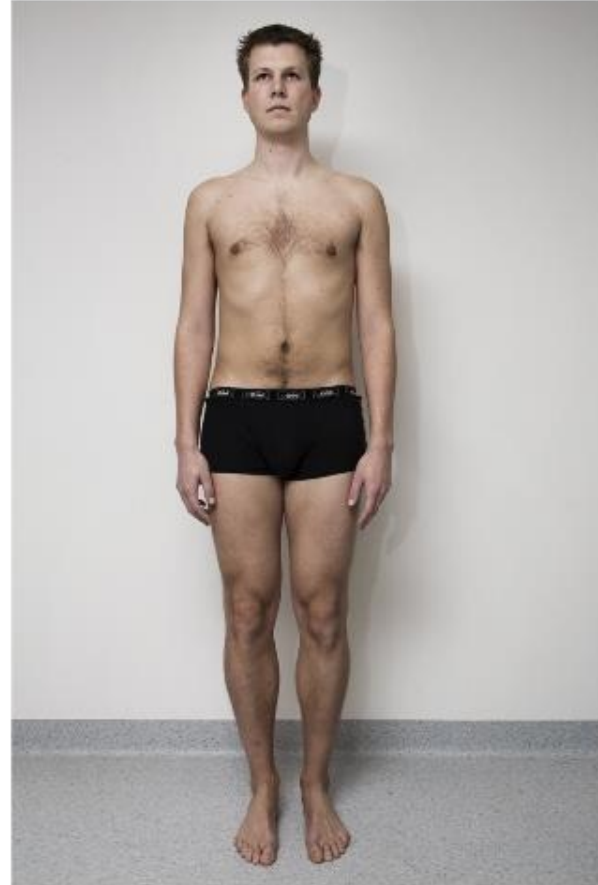
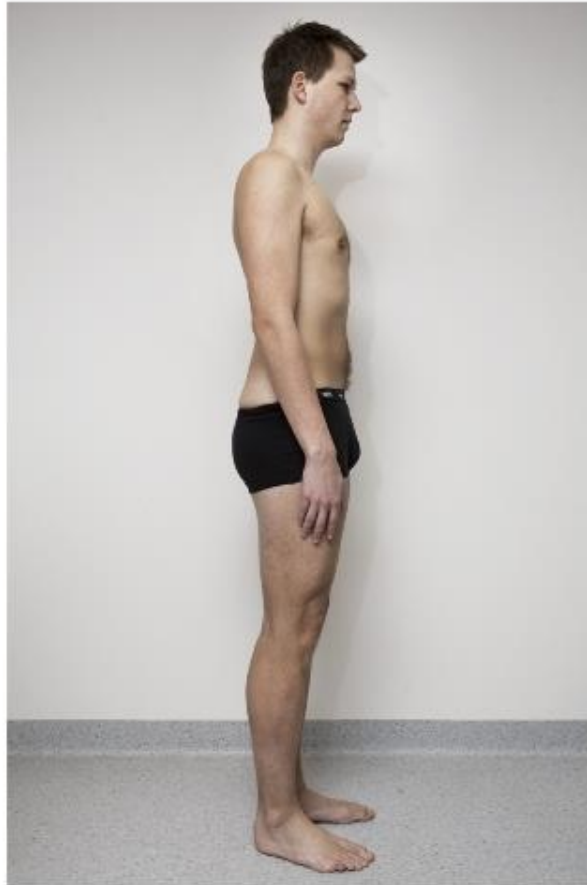
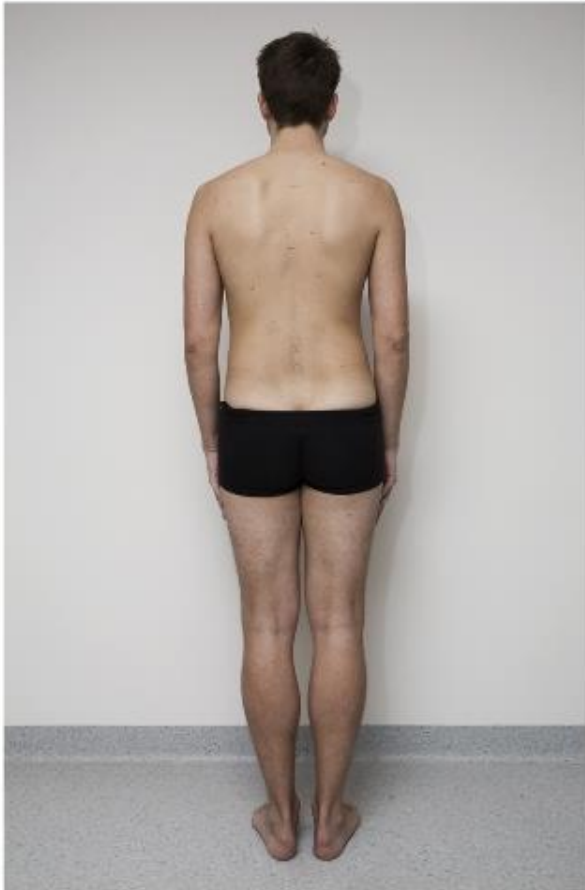FUNCTIE-ONDERZOEK

- ANAMNESE
- INSPECTIE
- BEWEGINGSONDERZOEK
 - actief
 - passief
 - geleid actief
- PALPATIE
- GEWRICHTTESTEN
(translatorisch onderzoek – Joint Play – Gelenkspiel)
- SPIERTESTEN
- NEUROSTATUS
- VASCULAIRE STATUS



Inspectie



- I. Bekkenkanteling – bekkentorsie
- II. Ilio Sacraal Gewrichtsdysfunctie
 - hypo hyper normaal
- III. Bekkenverwringing
 - ilium - ilium
 - Sacrum

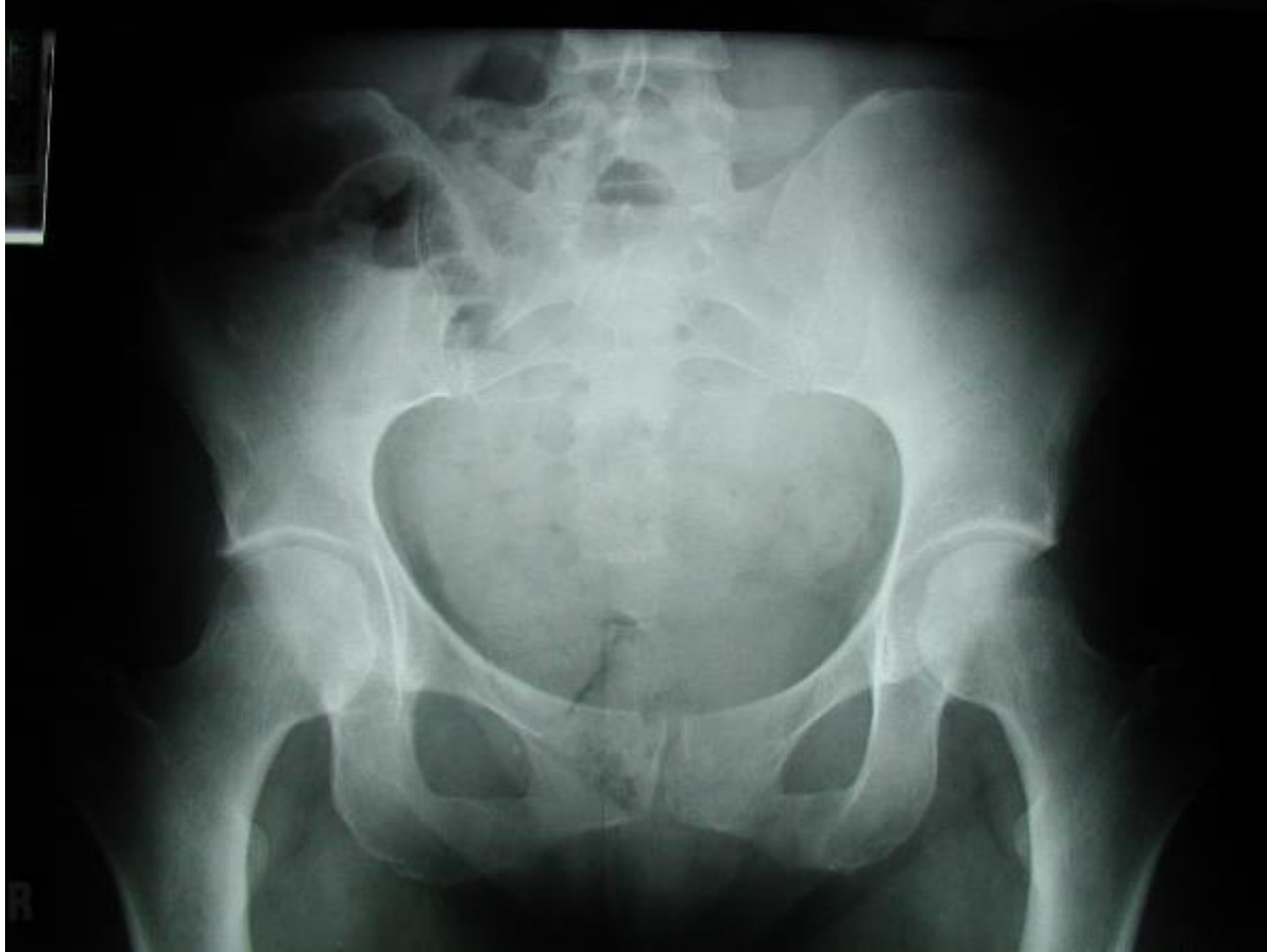

I. BEKKENKANTELING/TORSIE

- ***Bij verkorting:***
spreidstand: kanteling blijft
- ***Spierverkorting tensor fascia latae:***
spreidstand : kanteling valt weg
- ***Adductorenverkorting:***
spreidstand : kanteling wordt groter
- ***Heupgewrichtsblokkering***



Beckenrotation Re



- I. Bekkenkanteling – bekkentorsie
- II. Ilio Sacraal Gewrichtsdysfunctie
 - hypo hyper normaal
- III. Bekkenverwringing
 - ilium - ilium
 - Sacrum



II. ILIOSACRAALGEWRICHT DYSFUNCTIE : HYPO/HYPER

- **Voorloop in stand: vals + of -**
- **Rücklauffenomeen**
- **Spine-Test**
- **Hip-Drop-Test**



- Testbatterij Van der Wurff
 - Distraction
 - Thigh Thrust
 - Compression
 - Gaenslen
 - Patrick's sign
- Voorloop in lig (Derbolowski)



- I. Bekkenkanteling – bekkentorsie
- II. Ilio Sacraal Gewrichtsdysfunctie
 - hypo hyper normaal
- III. Bekkenverwringing
 - ilium - ilium
 - Sacrum



- Ilium – ilium

Stallingsdiagnose in stand
(crista, SIAS, SIPS)

- Stellingsdiagnose in lig (symfyse)

Rechts – links: gelijk

Rechts – links: niet gelijk

Anatomisch – functioneel korter been

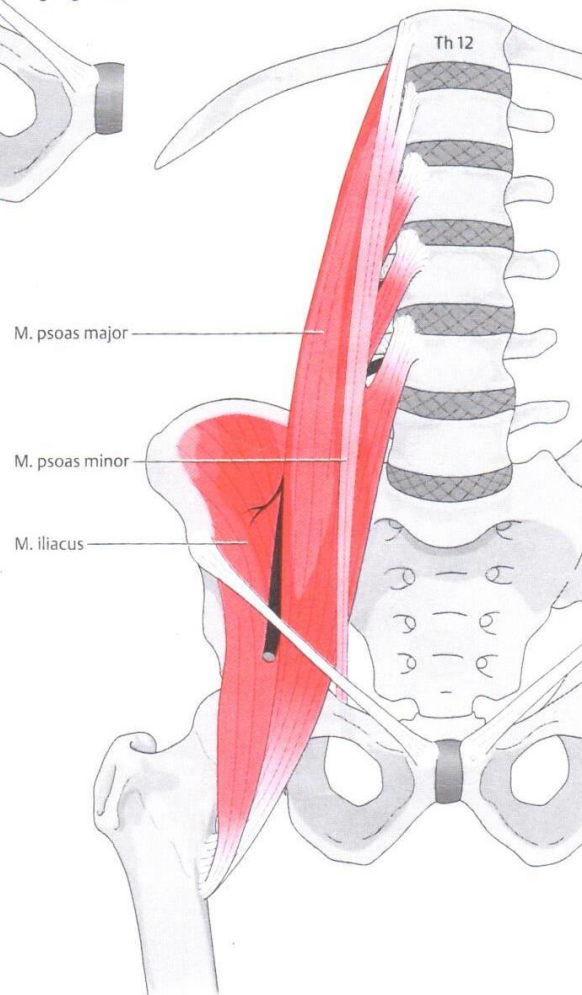
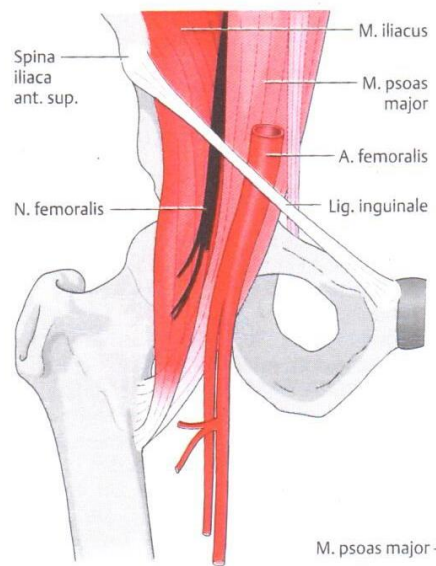


III BEKKENVERWRINGING

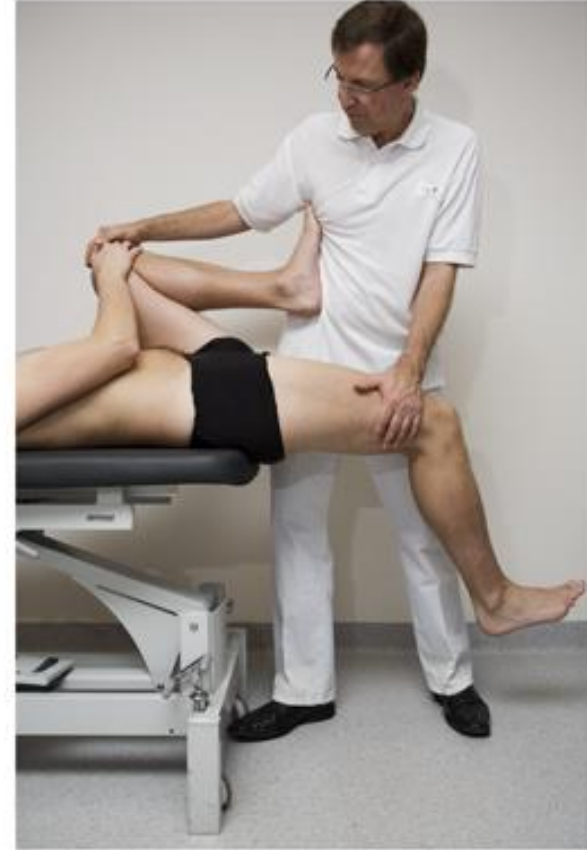
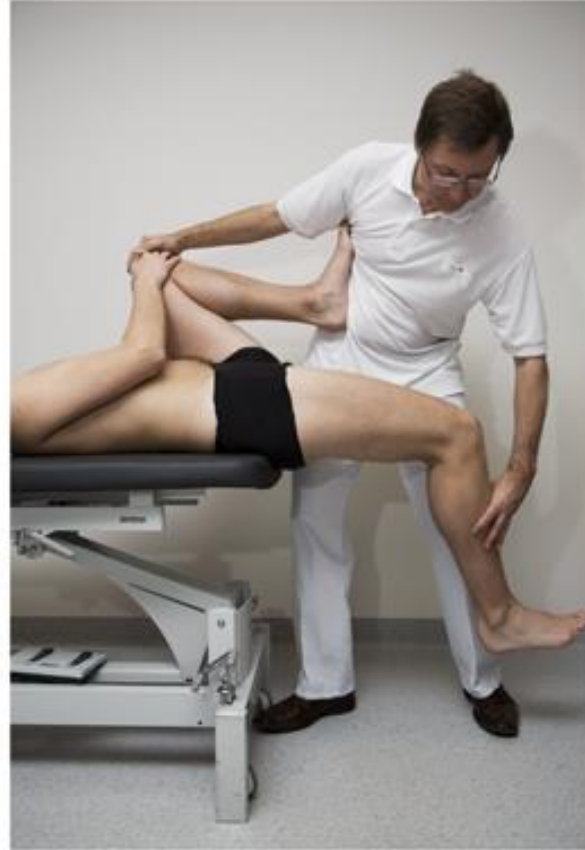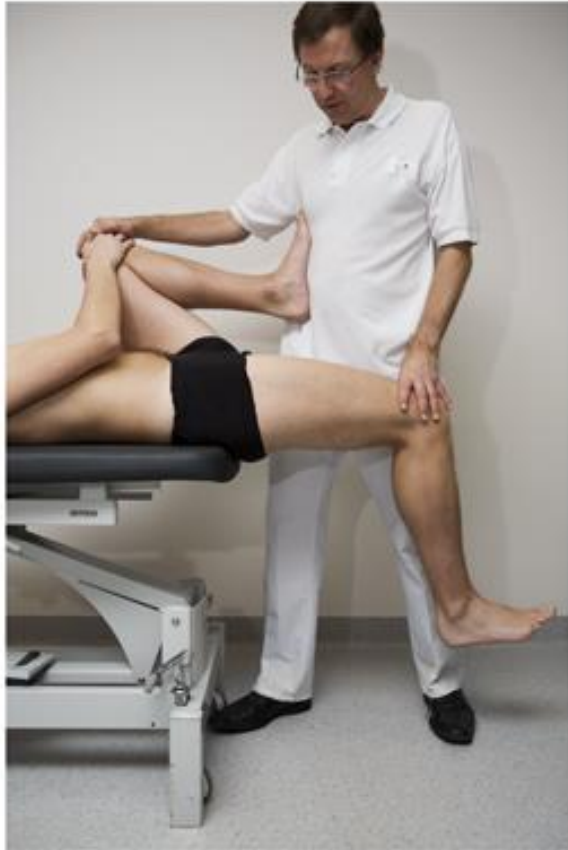- Ilium ilium
Spieronderzoek
(Tonus, kracht, verkorting, ...)

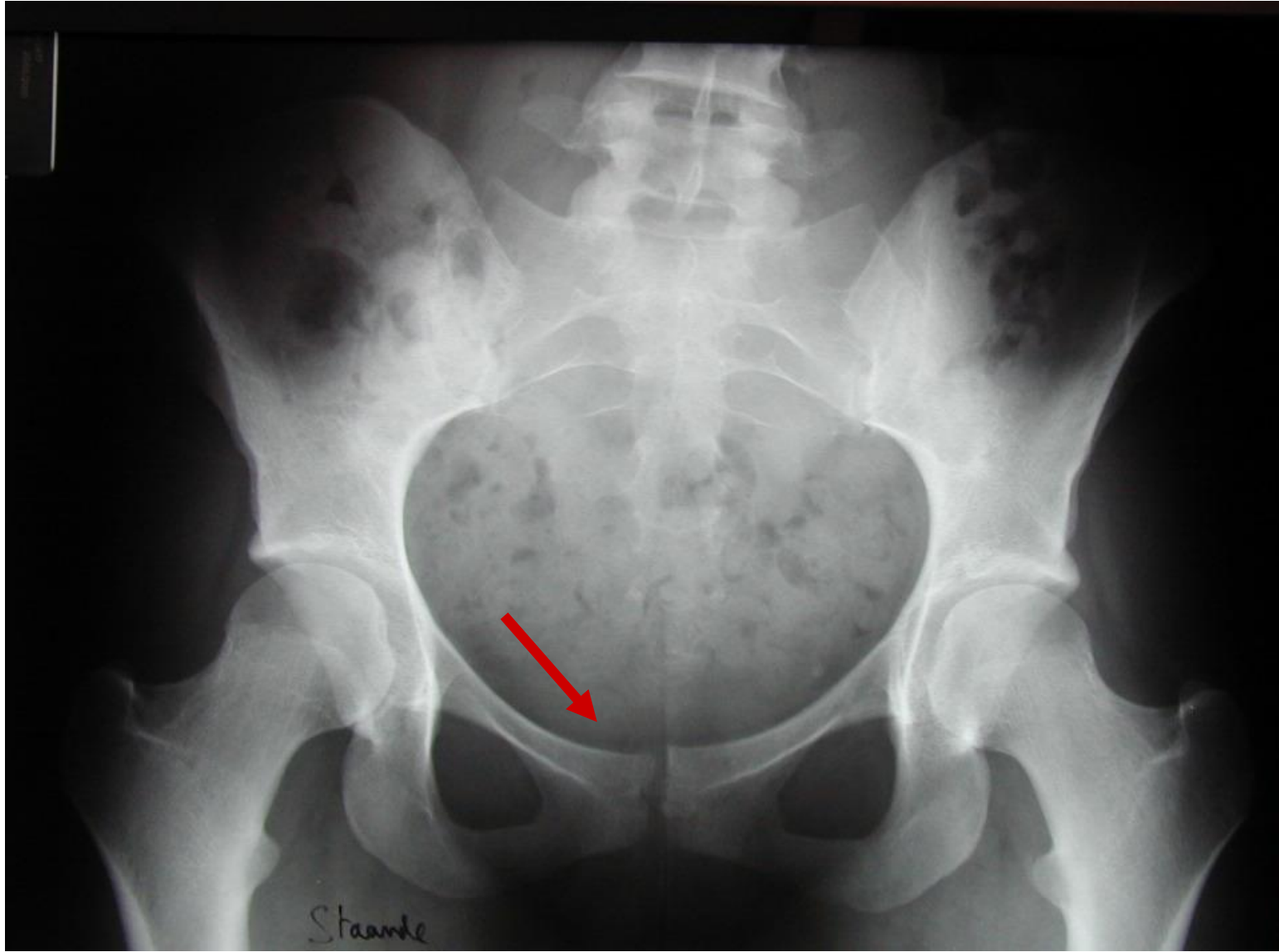
iliopsoas, hamstrings, buikspieren, adductoren, quadriceps,
tensor fascia latae, gluteus medius, maximus





Janda test



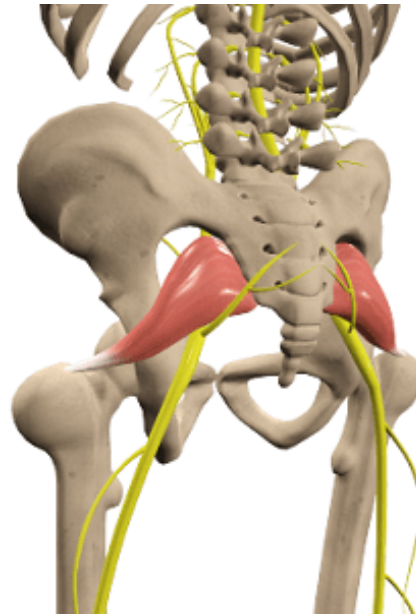


- I. Bekkenkanteling – bekkentorsie
- II. Ilio Sacraal Gewrichtsdysfunctie
 - hypo hyper normaal
- III. Bekkenverwringing
 - ilium - ilium
 - Sacrum

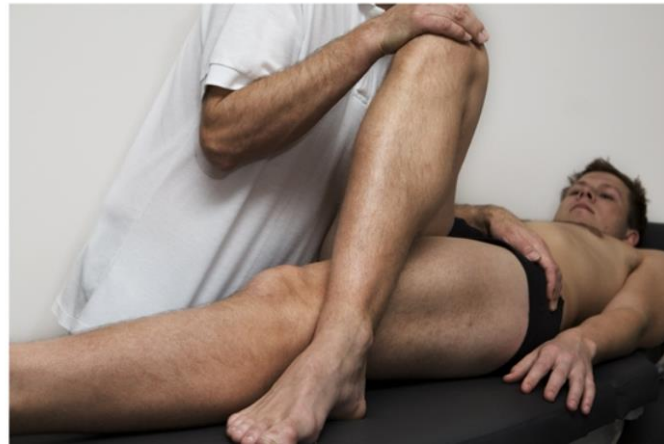
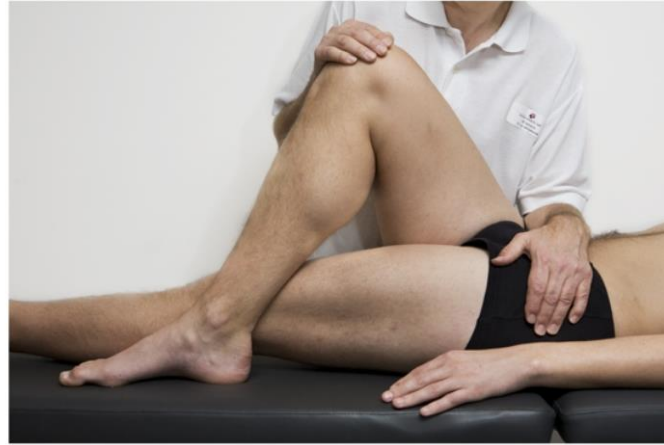
- Foutieve stelling van het sacrum
 - Stellingsdiagnose in stand, buiklig
 - Voorloop in zit
 - Spieronderzoek
 - Piriformis
 - Gluteus max.





Piriformis



Differentiële diagnose bij liespijn-pubalgie

(van musculoskeletale oorsprong)

- 1. Heupgewricht zelf**
 - Provocatietesten:
 - Teken van Patrick Kubis,...
 - Kapsulair teken
- 2. Peri-articulair heup**
 - Adductorentendinopathie
 - D - / +
 - A - / +
 - U - / +
- 3. SIG**
 - Testbatterij Van Der Wurff
 - Teken van Derbolovski
- 4. Thoracolumbale overgang**
 - Gerefereerde pijn
- 5. Andere**
 - Liesbreuk
 - Orgaan pathologie (uro – gyneco) ...



Pijn

lies

achterzijde bovenbeen
(S1)

lies

knie

Test

- Patrick Kubis teken
- voorloop fenomeen

kapsulair patroon
endo > abd > ext.

△

- bloccage ~ hypermobiel
- verwringing- ilium/ilium

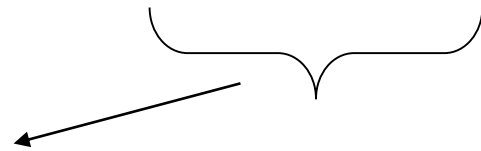
- sacrum in bekkenring

ruglig – buiklig



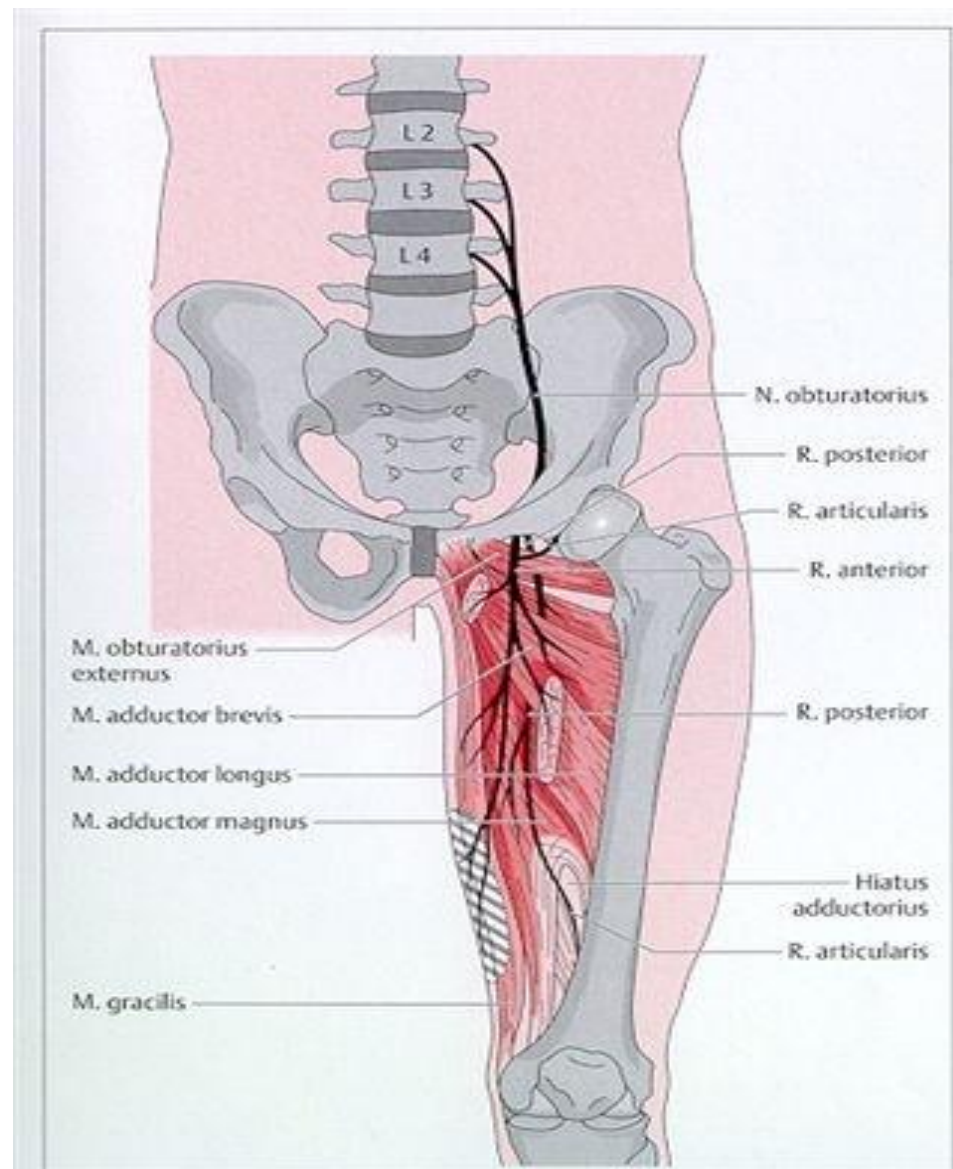
TENDINOGEEN...?...

- D+ + + + - - -
- A+ + - - + - -
- U+ - + - - + -



1. Heup
2. S.I.G. : blokkering/hypermob./verwringing
3. Thoracolumbale overgang
4. Bekkenschiefstand





Adductoorentendopathie

1. Rust
2. Antiflogistica
3. Fysio kiné
 - D.D.F. (Cyriax)
 - W.D.M
 - P.I.R. (Evjenth)
 - korte add.
 - lange add.
 - buikspier-tonificatie
 - (stretching?)
4. Infiltratie-PRP...

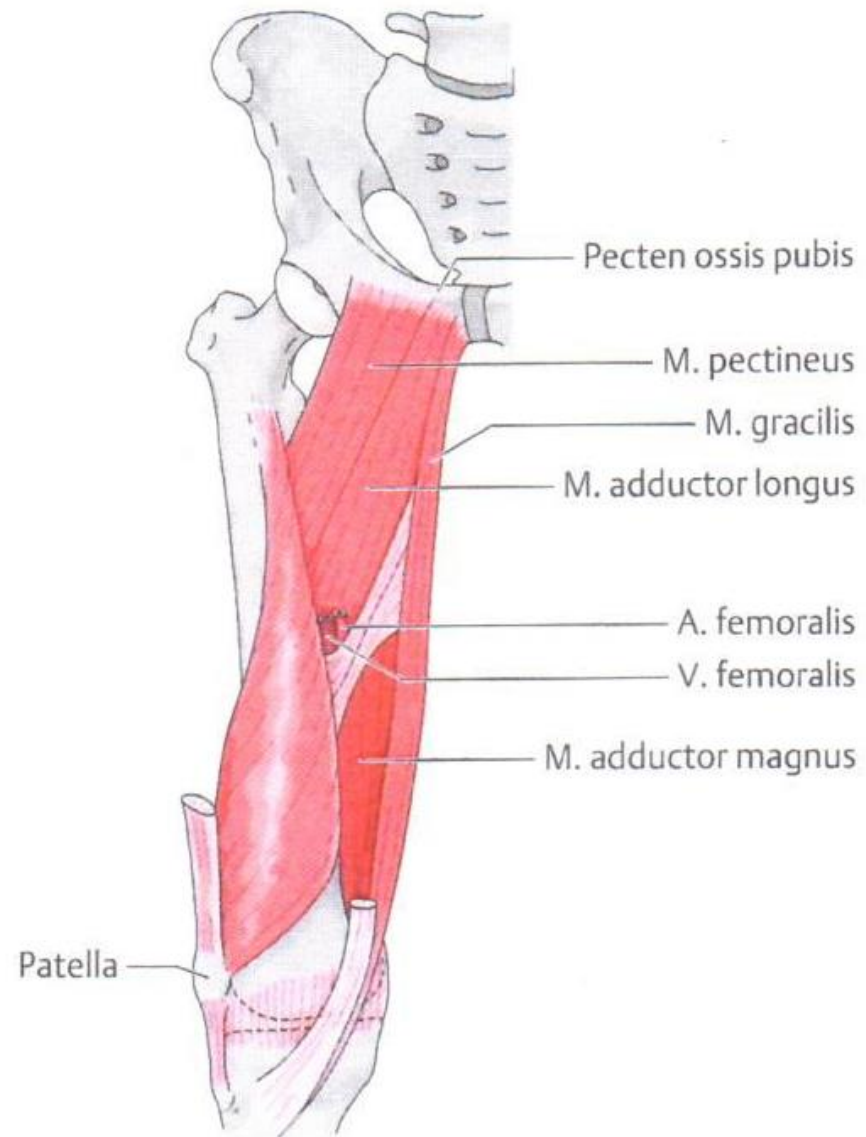


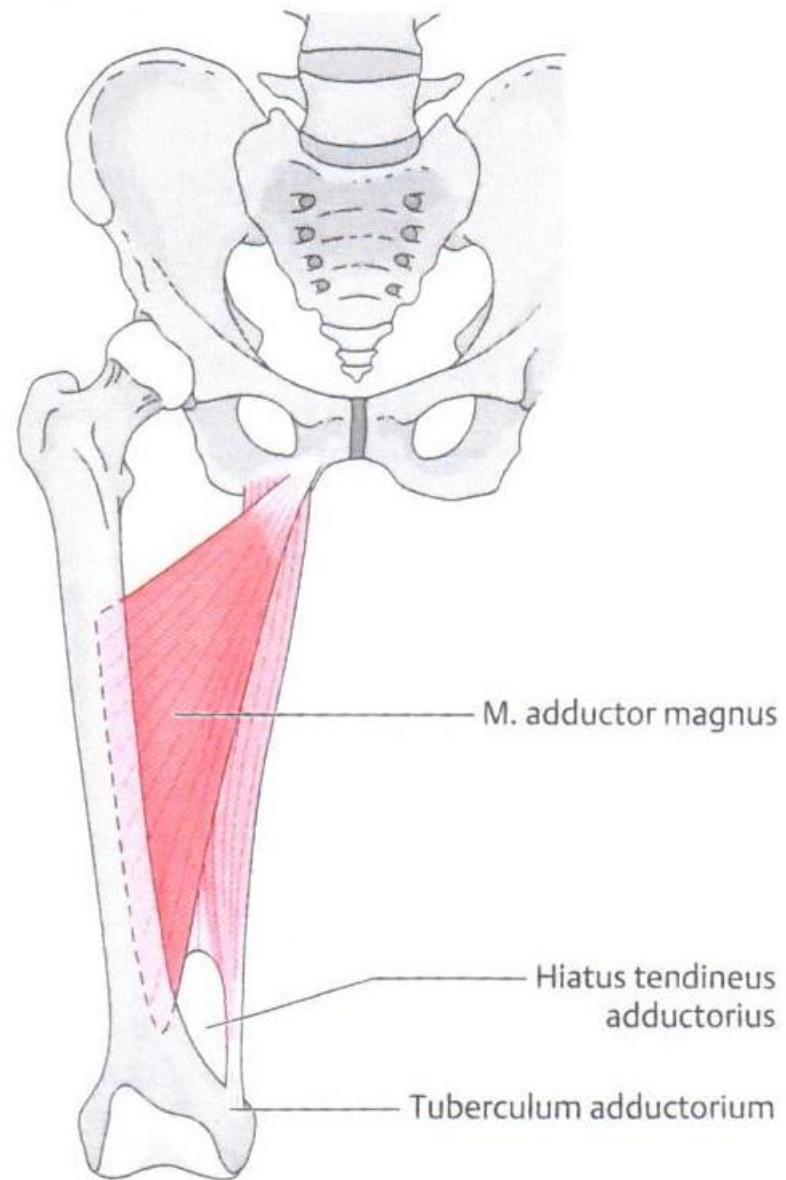
Therapie

niet als adductoren tendinopathie erkend :

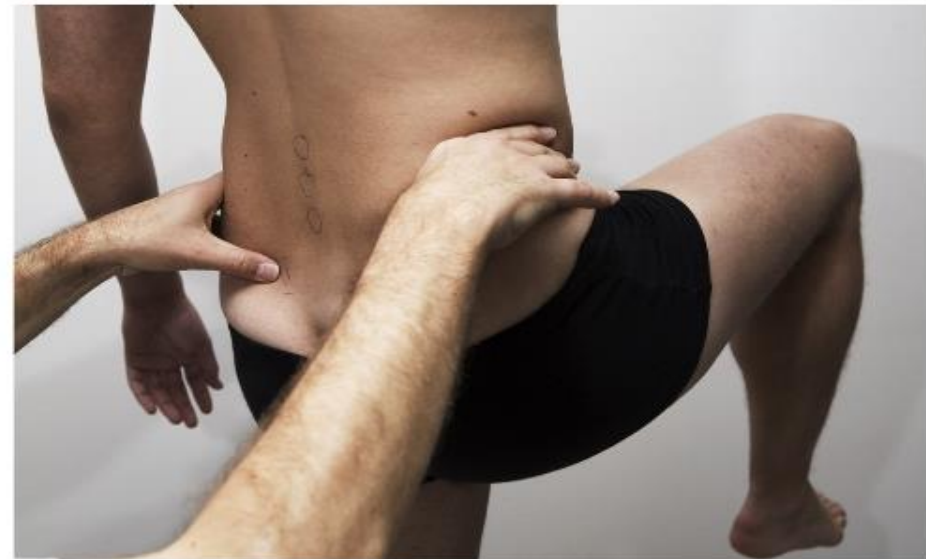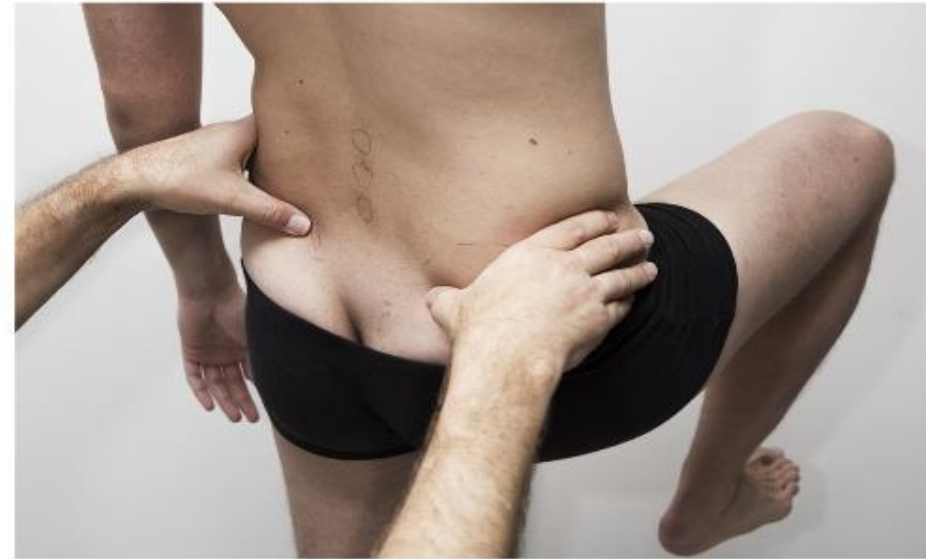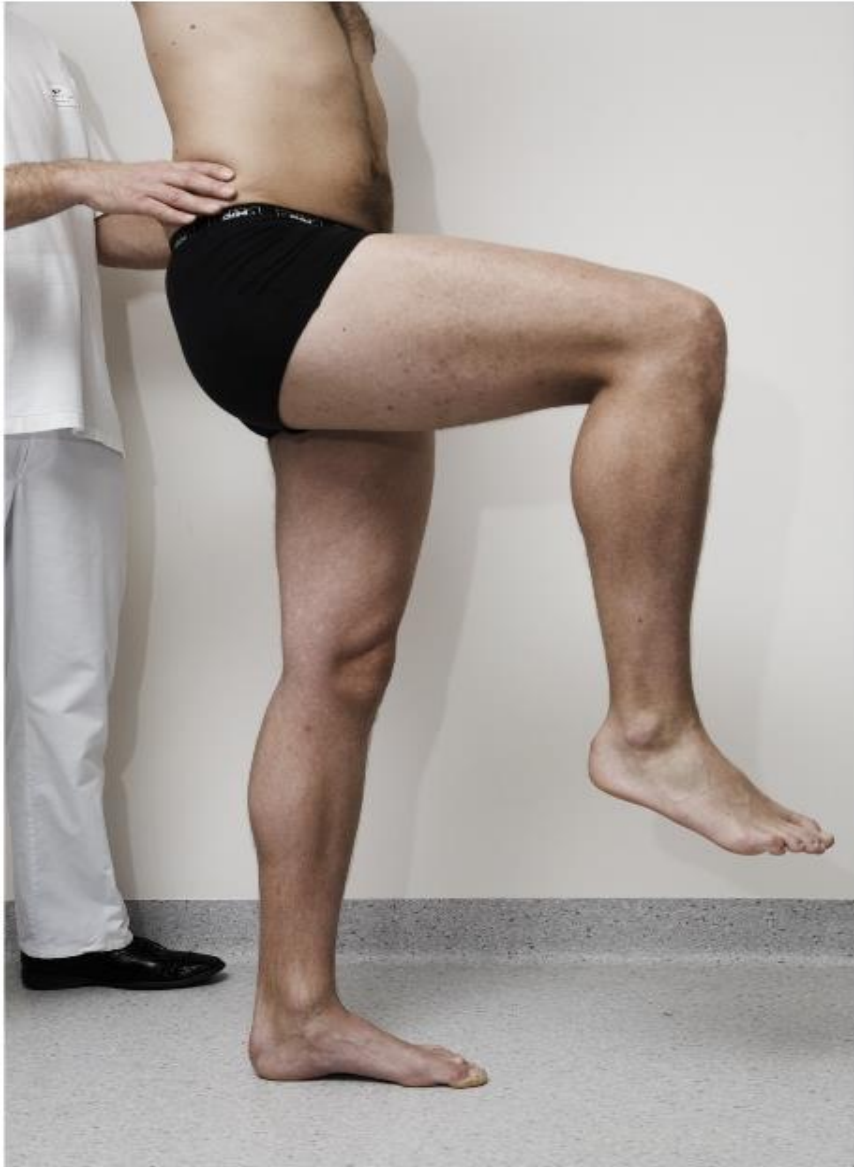1. Heupmanipulatie – mobilisatie
2. SIG manipulatie – verwringing wegwerken
3. ThLO
 -
 -
 -



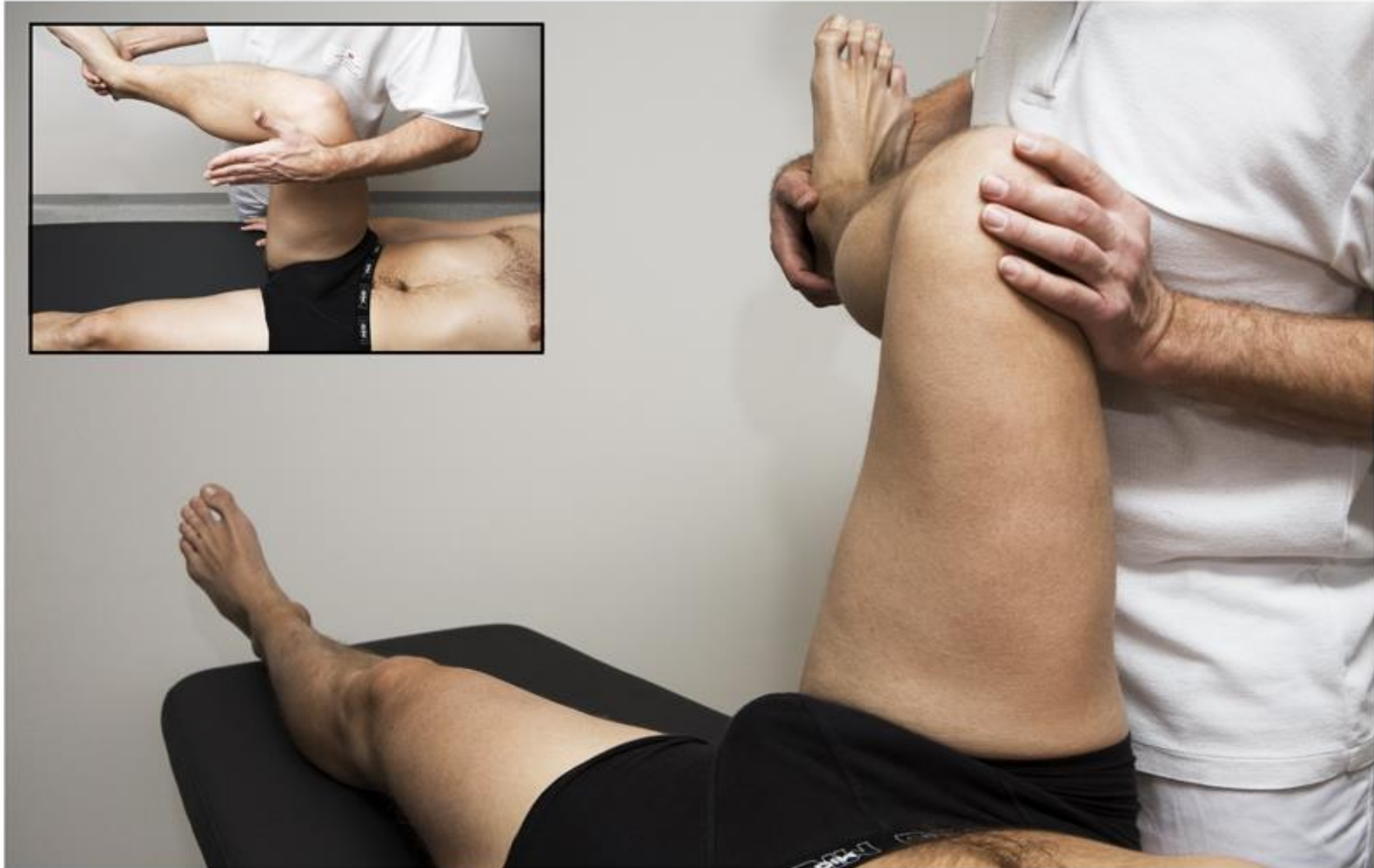



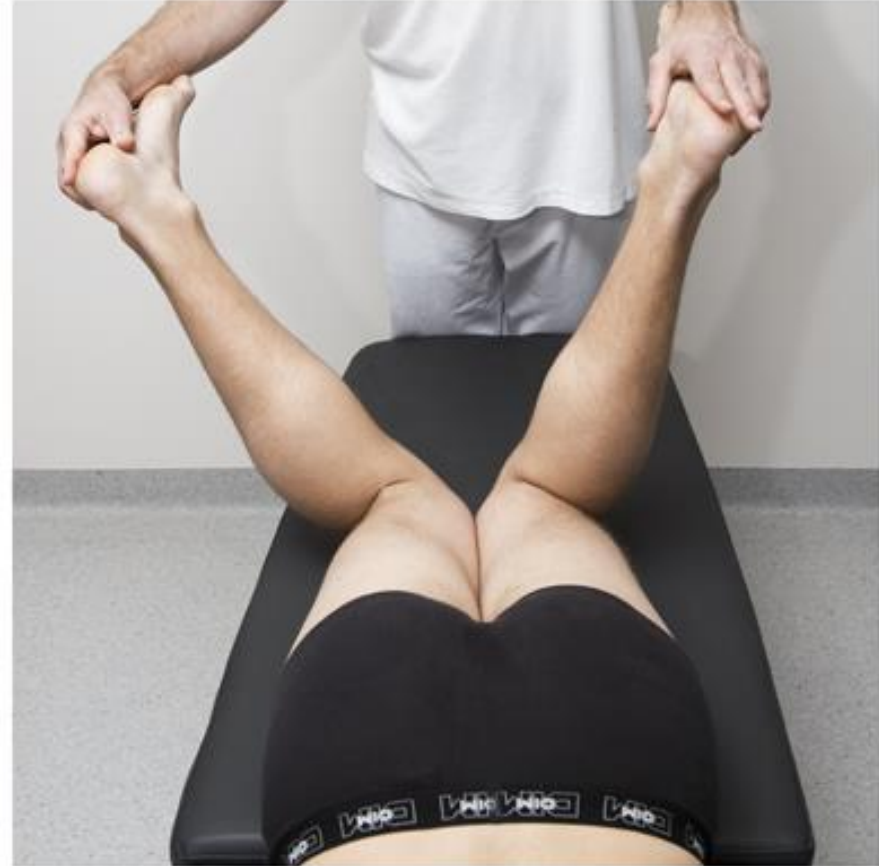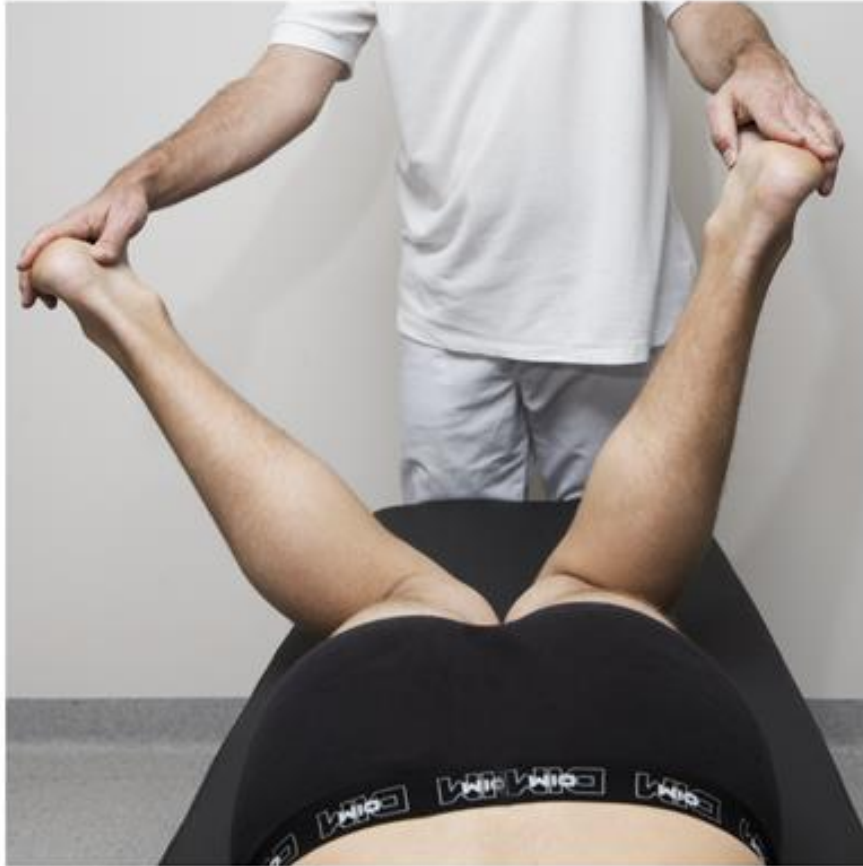Teken van Trendelenburg



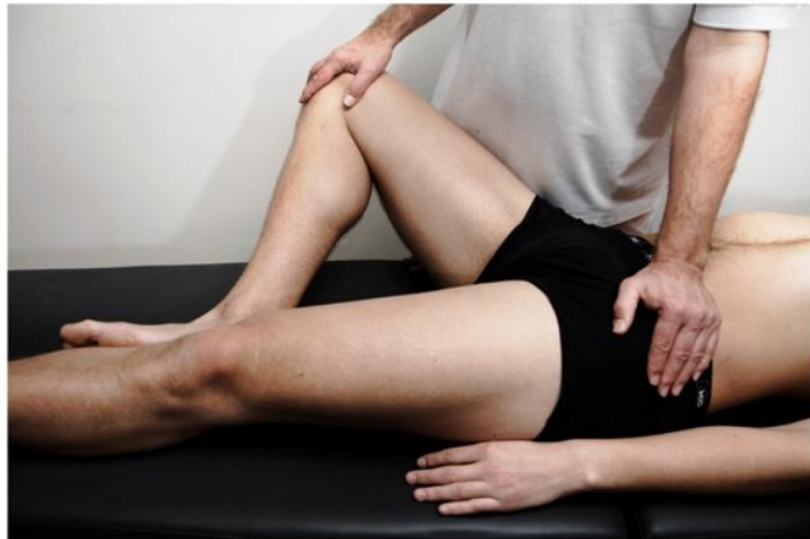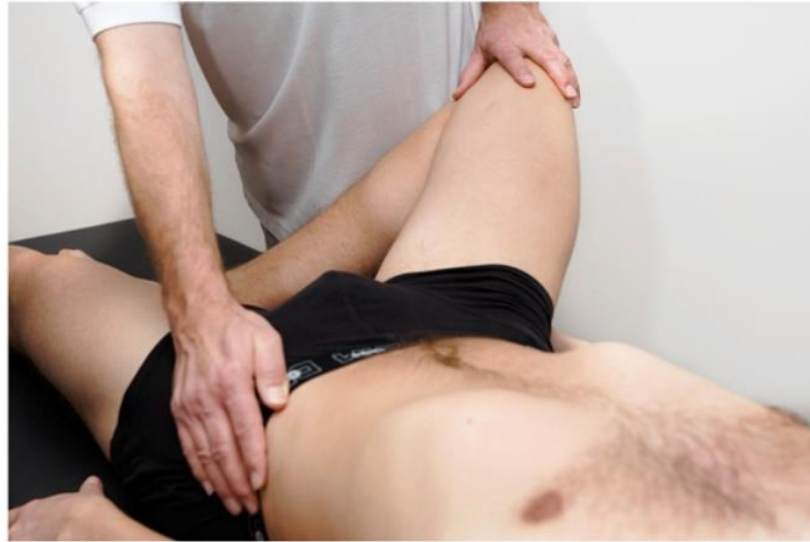Heupendo ruglig



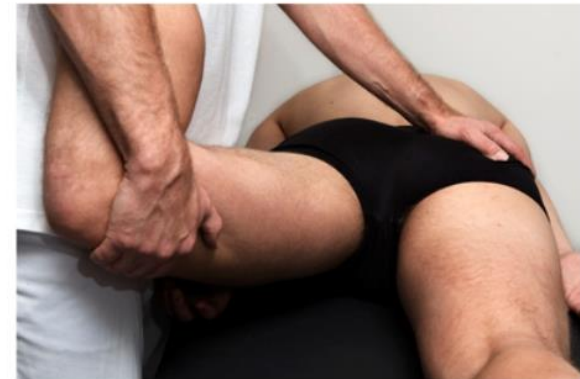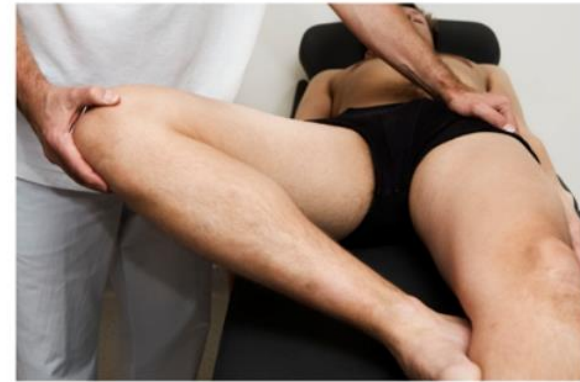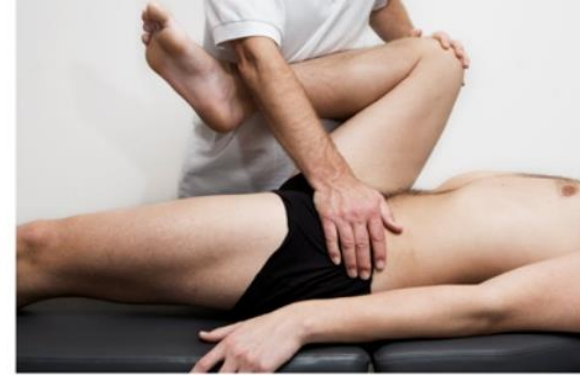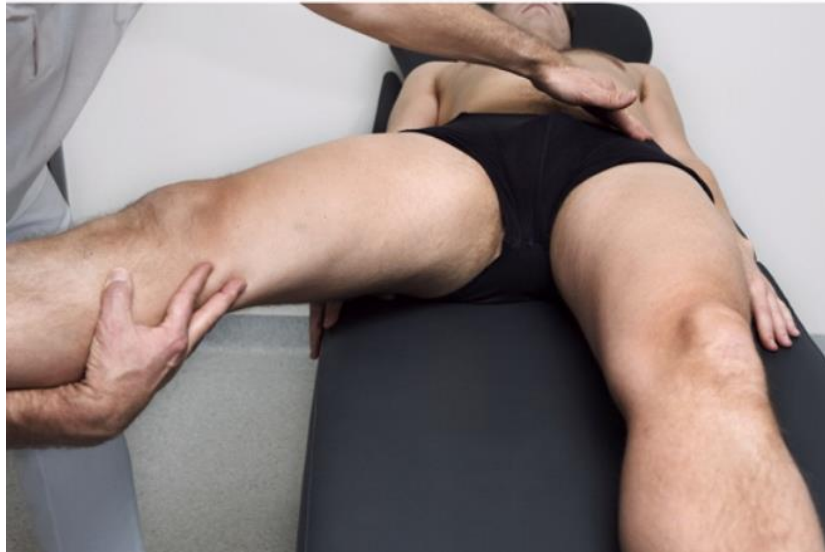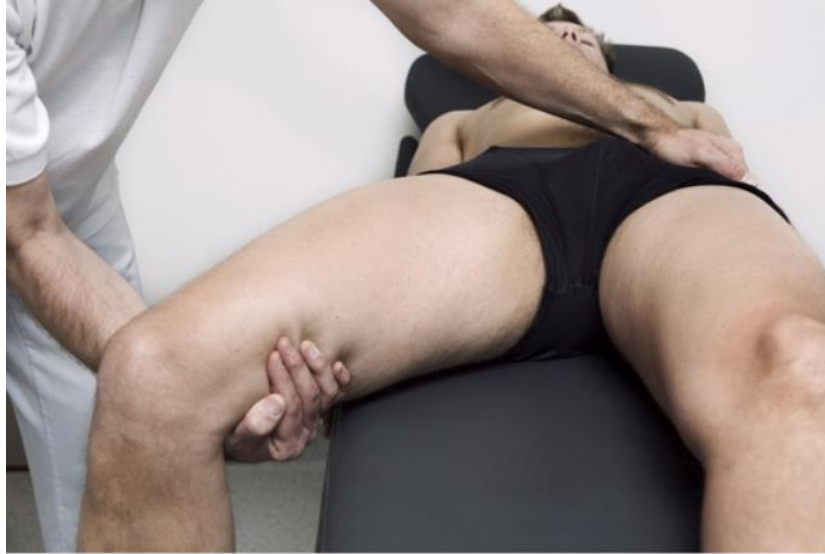Heupendo buiklig



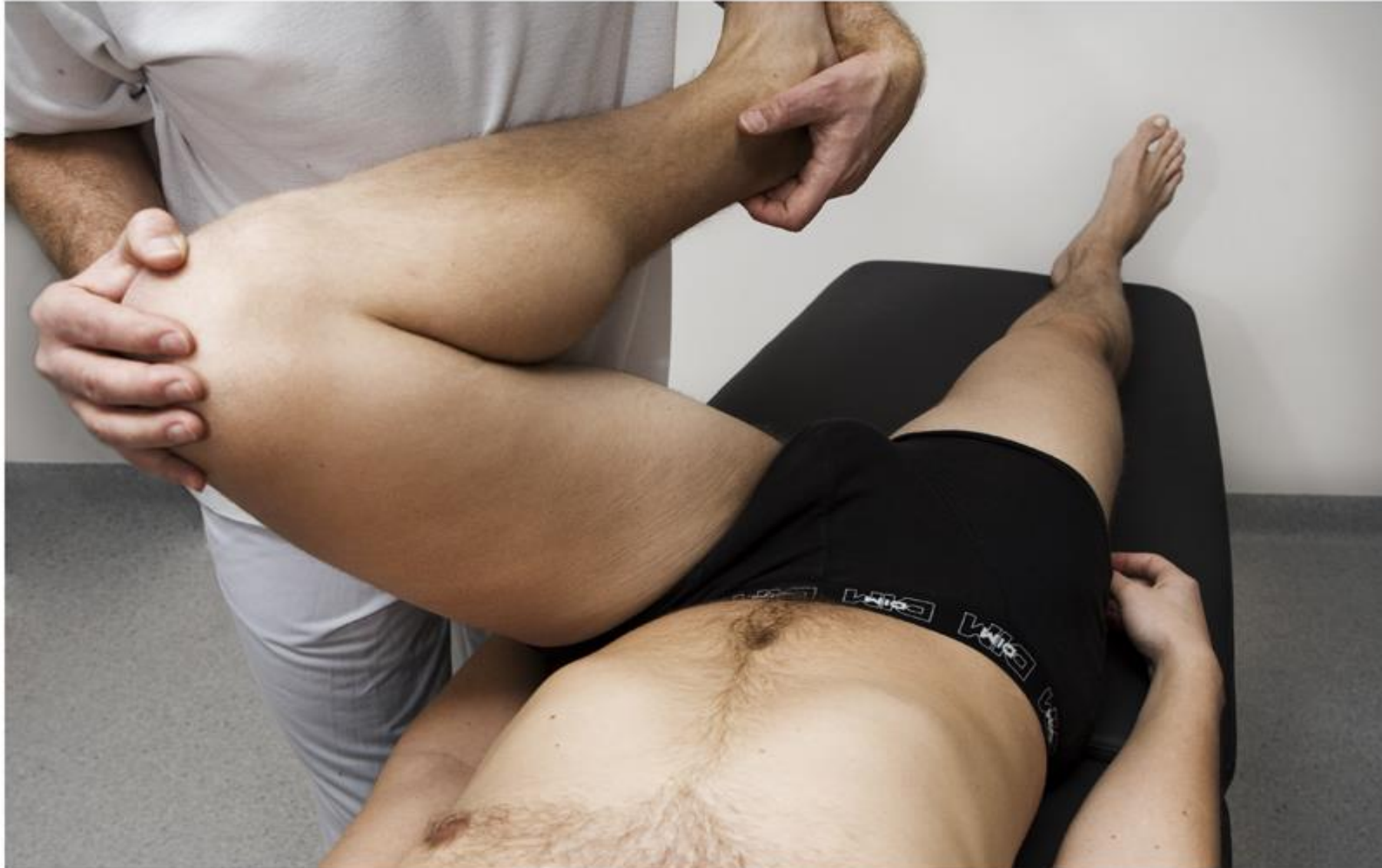Patrick Kubis - test



Adductoren

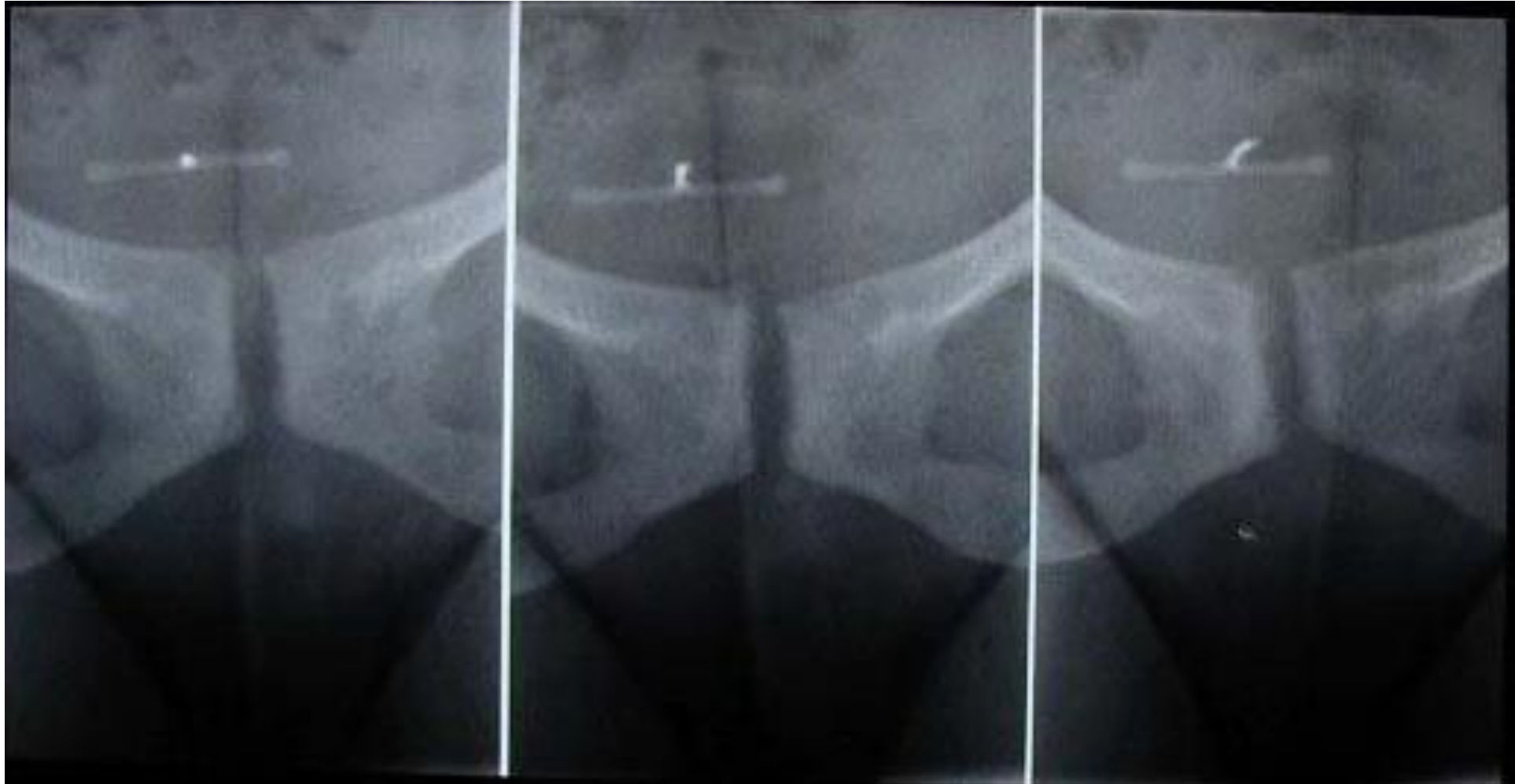

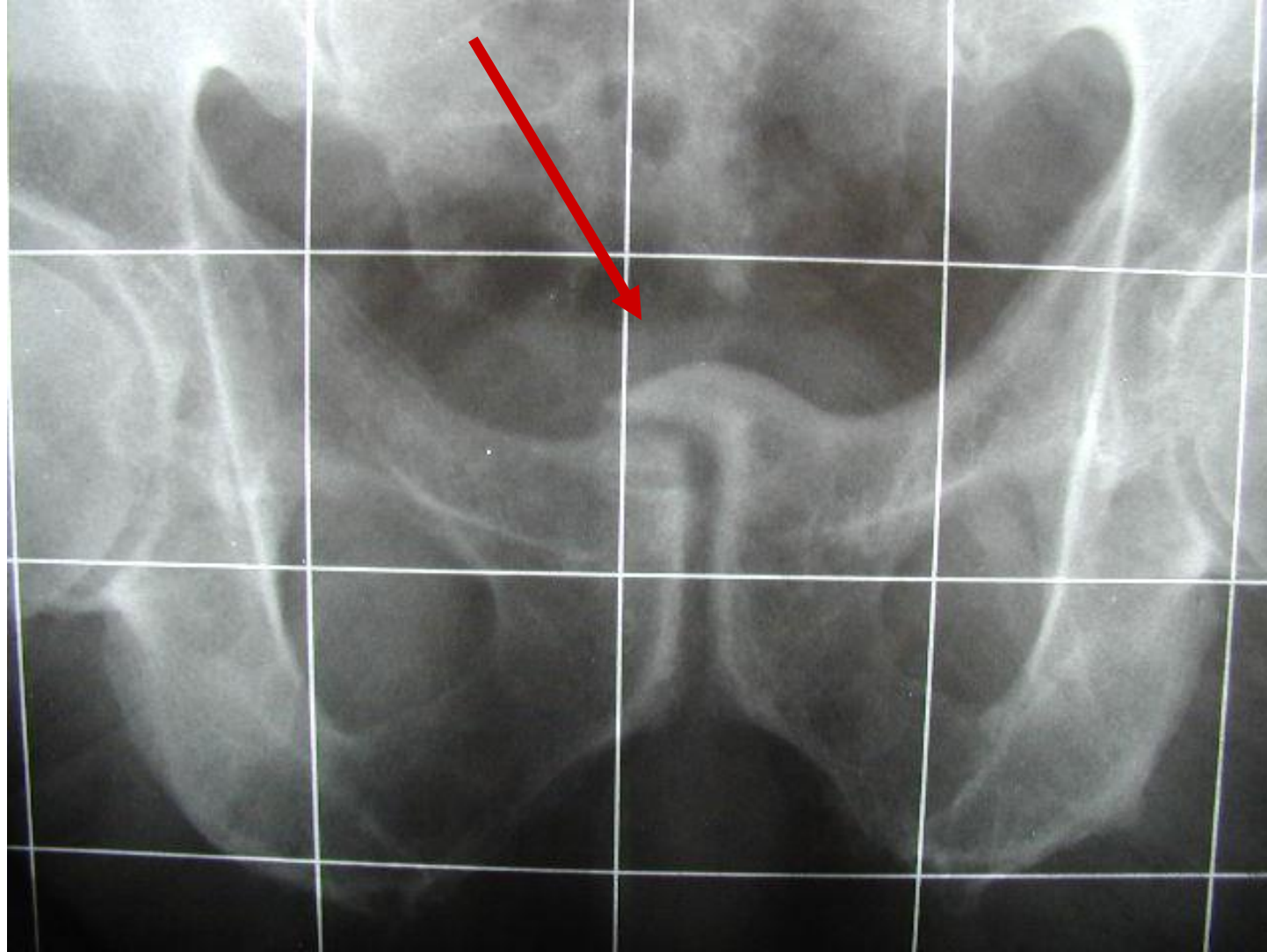
Heupflexie



Beckeninstabilität

Unipodale Belastung





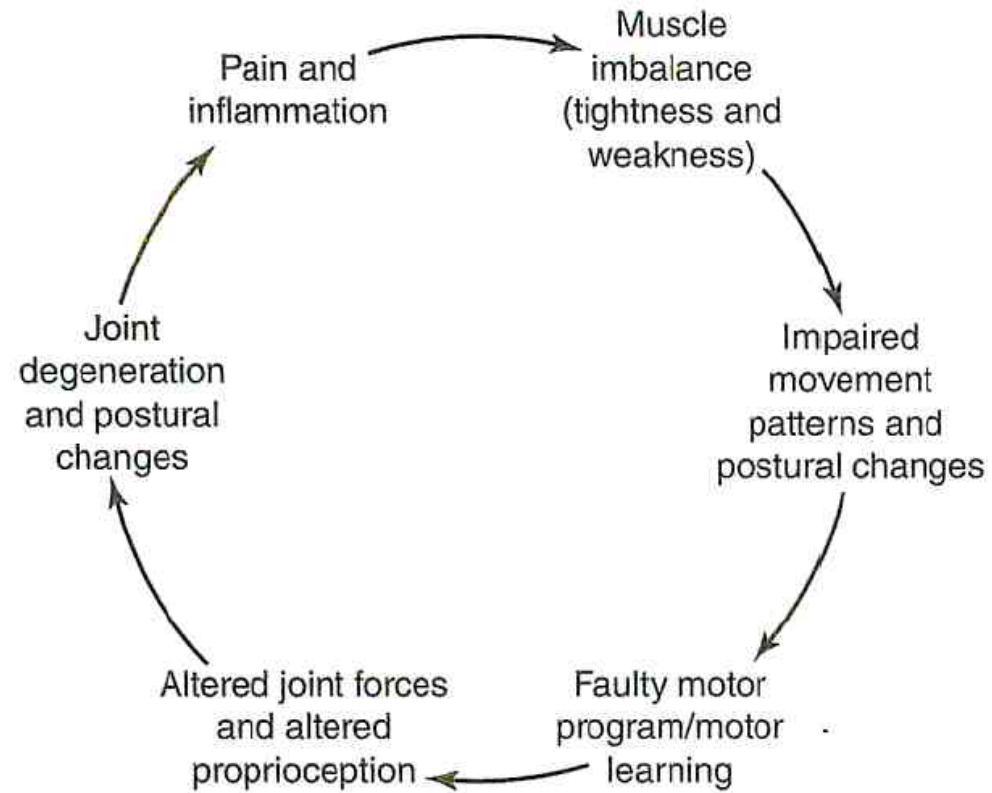


Figure 4.1 The chronic musculoskeletal pain cycle presented from a neurological perspective.



- ARTROKINEMATICA (GEWRICHTSMECHANICA)

primeert op

- SPIERMECHANICA



